CPP 7/0002-01
Acc. 1991-119-01 (v.2)

# Catalogue of the Mütter Museum

by

Guy Hinsdale, M.D.,

Curator 1883–1901.

Vol. II.

4000 -- GENITO-URINARY SYSTEM.

4010 -- BLADDER and PENIS. URETHRAL STRICTURE.

2028
120

The parts are well displayed. A probe passes through a narrow stricture 6 cm. from the meatus. The bladder contains three or four small diverticula. Rupture of the muscular coat.

Presented by Dr. Mutter.

4015 -- KIDNEY; ABSORPTION FROM URETHRAL STRICTURE.

2033
120

The upper portion of the ureter, 15 cm. in length remains attached to the kidney; it is widely distended having a diameter of about 3 cm. at the upper part and 1.5 cm. at the lower portion; the walls are attenuated. The condition was doubtless that of pyelitis. The distended ureter and pelvis, by means of numerous oval openings having a long diameter of about 1 cm., lead into extensive cavities developed in the tissue of the kidney. These cavities have diameters varying from one to four centimeters in extent; they are separated from each other by septa of fibrous tissue which in some instances have openings through which the contents may escape into neighboring cavities and thence into the pelvis. The upper portion of the kidney is destroyed more than the lower part. In the upper portion the kidney wall is in places not more than one or two centimeters in thickness. The capsule is apparently firmly adherent.

From Sir Astley Cooper's collection.

Presented by Dr. Mutter.

~~4020. Bladder and penis. Showing urethral false passages.~~
~~2034.~~
~~120~~
~~3.~~
~~Pres. by Dr. Wm. Pepper.~~



V 4017 X
2029
120
~~34~~

4017 -- BLADDER, PENIS, PROSTATE and RECTUM. URETHRAL STRICTURE. SUCCULATED BLADDER. URETHRO-PERINEAL FISTULA.

The urethra and bladder have been open and are well displayed. The rectum has been distended. A probe enters through the fistulous opening situated in the urethra 5 cm. from the neck of the bladder and emerges in front of the prostate gland in the perineum. Another probe passed through a narrow stricture situated 5 cm. from the meatus. The bladder contains over fifty small diverticula.

From an old sailor in a marine hospital, a patient of Dr. McClellan's.

Presented by Dr. Mutter.

V 4020 X
2030
120
B

4020 -- KIDNEYS, URETERS, BLADDER and PENIS. CYSTIC and CONTRACTED KIDNEY, HYPERTROPHIED BLADDER and URETHRAL FALSE PASSAGES.

The right kidney appears normal. The left kidney is small, contracted and contains numerous cysts which are situated inferiorily. The capsule did not strip so smoothly as upon the right side. The bladder walls are thickened. The urethra has been slit open and whalebone is seen in numerous false passages.

From a patient in the Philadelphia Hospital.

Presented by Dr. Wm. Pepper.

4020.[10] -- URETHRAL STRICTURE. HYPERTROPHIED BLADDER.

2034.
120
B.

The stricture seems to have been located in the membranous portion of the urethra. The bladder is very much contracted and hypertrophied.

Presented by Dr. Wm. Pepper.

4021 -- BLADDER, PENIS, URETERS and KIDNEYS.

2027.
120
B.

URETHRAL STRICTURE. SACCULATED and DISTENDED and ULCERATED BLADDER. HYPERDISTENSION of the URETERS and ACUTE NEPHRITIS.

This specimen is a remarkable one and well displayed. The urethra and bladder are laid open for inspection. The distance from the fundus of the bladder to the meatus urinarius is 40 cm.; to the neck of the bladder, 20 cm. The stricture was situated in the membranous portion of the urethra. The bladder is greatly distended, abounds in diverticuli and the mucous membrane is greatly corrugated. A large cavity 5 cm. in diameter with ulcerated walls is situated to the left of the neck of the bladder.

The ureters are distended and are well displayed. The right one has, near the kidney, a diameter of 4 cm. The left is laid open and shows extreme distension throughout its entire course and a diverticulum 1 cm. in diameter near the pelvis. The left kidney is small and has probably undergone inflammation with suppuration. The right kidney appears normal.

Pres. by Dr. Mütter.

4028.1 Male Genital Organs Amputated

4026 -- PENIS. URETHRAL STRICTURE and FALSE PASSAGES.

2035
120
3

The urethra having been laid open it is difficult to say where the stricture was situated. False passages are seen in the bulbous portion of the urethra.

Presented by Dr. Mutter

4028 -- PENIS and TESTICLES, AMPUTATED by a MAN in an ATTACK of MANIA A POTU.

2036
120
B

From C. H., a cigar-maker; married and the father of three children. In an attack of Mania á potu, he wandered into a "wood near Girard College" and under an hallucination that a crowd of demons had caught and secured him demanding that he sacrifice his visibility, he picked up a piece of a porter bottle with which he hacked off his penis and testicles with the scrotum, and in addition made a deep cut in his left arm. When found he was sitting on the ground bleeding very profusely "and actually gnawing at his lacerated and bloody organs".

He was admitted to the Philadelphia Hospital March 8, 1853. One of the spermatic cords was tied; the other could not be found. There was no hemorrhage.

Four months later the wound had healed well. One year later he appeared well, with bushy whiskers, and masculine voice, and quite robust. Eighteen months after castration phthisis developed of which he died December, 1854.

Presented by Dr. W. T. Taylor, M.D.

(See Amer. Jour. Med. Svi. July 1855, p. 85.

15

Missing

4028.1 Male Genital Organs. Amputated.

Presented by Dr. G. G. Davis.

4029 -- PENIS; AMPUTATED.

2037.
120
4

Presented by Dr. Ruschenberger.

4053 -- PENIS. EPITHELIOMA.

2039. The under surface of the head, neck and body of the penis are the seat of an ulcerated and prominent growth, having elevated margins and a shaggy, almost velvety, surface. Its extent is about 5 cm. long and 3 cm. broad.

Presented by Dr. Mutter.

4100. Carcinoma of Prostate with extensive involvement of bladder.
4100.054 Middle lobe of prostate
Supra pubic prostatectomy. Mr. Walter, Methodist Hospital 12/12/03 by Dr. Roberts
Presented by Dr. Roberts.

4110 -- HYPERTROPHIED PROSTATE and BLADDER.

1943
119
2

The prostate is enormously enlarged, having a diameter of about 10 cm. The bladder appears healthy.

Presented by Dr. Mutter.

4110.10 -- HYPERTROPHIED PROSTATE WITH BLADDER.

1944
119
2

The prostate has been laid open.

Presented by Dr. Mutter.

4110.15 -- HYPERTROPHIED PROSTATE WITH BLADDER.

1945
119
2

The prostate is entire; it has a diameter of about 6 cm. The mucous membrane of the bladder is deeply wrinkled. The bladder walls are not hypertrophied and the capacity was large.

Presented by Dr. Mutter.

4110.20 -- PROSTATE WITH BLADDER. HYPERTROPHY.

1946
119
2

The hypertrophy was considerable; the bladder walls are hypertrophied; the mucous membrane is deeply wrinkled. Probes have been passed through the urethra and ureters.

Presented by Dr. Mutter.

4110.25 -- HYPERTROPHIED PROSTATE WITH BLADDER.

1947
119
2

The prostate has been laid open as well as the bladder. The hypertrophy is only moderate; the bladder walls have not participated. The capacity is excellent.

Presented by Dr. Mutter.

4110.30 -- HYPERTROPHIED PROSTATE WITH BLADDER.

1946
119
2

The hypertrophy is very slight; the bladder walls are somewhat thickened. A portion of each ureter is seen leading into the bladder.

Presented by Dr. Mutter.

4110.35 -- HYPERTROPHIED PROSTATE AND BLADDER.

1948
119
2

The prostate has a vertical diameter of about 4.5 cm. The bladder is hypertrophied.

Presented by Dr. Mutter.

4121. – Tuberculous caesation of the prostatic urethra resulting in cavity almost as large as the bladder. The bladder shows no evidence of tuberculosis but there is a tuberculous ulcer in the ureter.

Case from P. G. H. medical service of Dr. Boston and Urologic service of Dr. Kinney.

Reported by Dr. McCahoy and Dr. J. Alex. Clarke.

4200 Closure of Exstrophy of the Bladder, forming a new perineal floor

2032
120
4

pres. by Dr. John B. Roberts



4110.40 -- HYPERTROPHIED PROSTATE AND BLADDER.

1949
119
2

The prostate has a lateral diameter of about 6 cm. The vesical walls are also thickened.

Presented by Dr. Mutter.

4110.45 -- HYPERTROPHIED PROSTATE; WITH BIADDER.

#1495
119
2

The prostate is considerably enlarged. The bladder is of ample capacity, and is not thickened.

Presented by Dr. Mutter.

4110.50 -- HYPERTROPHIED PROSTATE; WITH BLADDER.

1997 (Path)

Presented by Dr.J.L.Stewart, Erie, Pa.

4115. -- ABSCESS OF THE PROSTATE.

2040
120
4

Presented by Dr.J.M.Corse.

4200.05 -- SPECIMENS FROM A CASE OPERATED ON FOR EXSTROPHY OF THE BLADDER. Missing

(Path)
1950
119
3

4200,10 Missing
7030

Specimens from a case of Exstrophy of the Bladder. Lithotomy after partially successful closure: subsequent construction of a perineal urethra from scrotal tissue.

The patient was a child of eight who underwent three operations for this defect. After the second operation, the urine became offensive and calculi, ten in number, formed in the new bladder. The child died on the fifth day after the last operation; the left kidney was found riddled with small abscesses. The ureter on this side is double and shows great inflammatory enlargement and thickening of its walls. The pelvis of the kidney and the double ureter were filled with pus. Just before the two ureters of this kidney reached the bladder, they united and opened into the bladder by a common orifice.

The right kidney and ureter appeared to be normal.

Presented by Dr. John B. Roberts.

4201. -- BLADDER; DOUBLE.

The specimen consists of two bladders of equal size, lying side by side, united laterally by contact of their walls. They are both apparently of normal size, and do not in any way appear to be diseased. A whalebone has been placed in a small opening in the septum. The two ureters went to their corresponding bladders. Whalebones have been placed in the ureters and vesicular seminales.

Presented by Dr.J.M.Da Costa.

4205. Rudimentary Penis Prepuce and tissue around to close an Ectrophy of the Bladder. Presented by Dr. J.B.Roberts.

4211. -- BLADDER: HYPERTROPHY.

Presented by Dr.John H.Packard.

4211.05 Bladder; Hypertrophy

4211.10 -- BLADDER; HYPERTROPHY.

Presented by Dr. John H.Packard.

4215. -- BLADDER, PROSTATE AND PENIS. CYSTITIS AND GONORRHEA.

The mucous membrane about the neck of the bladder is softened, and has been detached from the deeper layers. This was apparently due to cysti-

IX

4215.10 Bladder.

Glass rod passes through wounds of entrance and exit. Hemorrhagic cystitis shown by opening in posterior wall.

Death from cystitis after 7 days.

Pte. C.J.W. 9543. 13/17 Bde. Wounded 22/7/17. Shrapnel ball, fractured pelvis and traversed bladder (see specimen of pelvis No. 40).

Surgeon J. H. Gibbon. Pathologist E. B. Krumbhaar.

Presented by U. S. Base Hospital No. 10.

tis following gonorrhoea. Shreds from the mucous membrane of the urethra hang down.

Presented by Dr. Mutter.

4221. -- BLADDER, RECTUM AND PROSTATE. PAPILLOMA OF THE BLADDER.

1957
119
3

The specimen has been well dissected, so as to show the relations of the parts. A longitudinal cut exposes the interior of a small, thickened bladder. Rising from the trigone, and occupying the lower half of the posterior wall, is a papillary growth, covered with fine, velvety tufts. The tumor has a broad attachment, and is of considerable bulk, measuring nearly 4 cm. in the vertical line. The prostate is of normal size. A whalebone enters the urethra at the neck of the bladder immediately below the tumor, and appears below the prostate. The bladder is contracted. The mucous membrane about the tumor appears healthy, but the muscular coat is greatly hypertrophied. The left ureter has been dissected, and is enlarged.

Presented by Dr. J. H. Packard.

4223. -- BLADDER FIBROMA.

1958
119
3

The trigone and inferior portion of the posterior wall is covered with dendritic growth, nearly filling the cavity of the bladder. These processes

4228. Watch guard removed from Bladder.
2010
119
3. Pres. by Mr. F. R. Packard.

4229. Gall Bladder with Gall stones.
2011
119
3. Pres. by Mr. F. A. Packard.

4230.
2012
119
3.

4300.05 Kidney; single.
2026.
120
2



consist of groups of rounded bodies attached by small pedicles to a common base. They are firm and of smooth surface, and have diameters of .5 to 1.5 cm. The muscular wall of the bladder is somewhat hypertrophied.

Presented by Dr. Mutter.

4227. -- BLADDER. CALCAREOUS DEGENERATION AND HYPERTROPHIED PROSTATE.
1999
119
3.

The mucous surface of the bladder is exceedingly rough, the walls are thickened, and have undergone calcareous degeneration to a marked degree, being covered with tuft-like deposits.

The prostate is enormously enlarged, and varies in diameter from eight to nine centimetres. There is, in addition, an outgrowth from the prostate about 5 cm. in diameter.

Presented by Dr. Mutter.

4300. -- KIDNEY; CONGENITALLY SINGLE; SINGLE URETER.
2022.
120
2.

From Mrs. M.L.C., aet 53 yrs., who had for several years suffered from symptoms indicating cerebral disease, and possibly disease of the stomach. The immediate cause of death was exhaustion and imperfect nutrition. At the autopsy the body was found emaciated; skull very thick, and destitute of diploe. There was some turbid serum under the arachnoid. The brain matter generally was softened

especially on the right side. In the corpus striatum of the left side there was an apoplectic clot about 1 cm. in diameter, not recent,- and the surrounding cerebral substance was somewhat wrinkled. The right lobe of the cerebellum was soft; the markings of the arbor vitae curiously indistinct, and the corpus dentatum wasting. All of the arteries about the base of the brain were atheromatous. Old tubercules were found in the lungs. The heart was large and fatty. Between the layers of the pericardium around the base of the organ old lymph. One flap of the mitral valve adherent; other valves healthy. Thick and fatty gastro-colic omentum adherent to the viscera. Stomach vertical, but normal; liver, fatty; a large gall-stone distended the gall bladder. Spleen, small and on section showed very numerous specks of whitish deposit like tubercle; microscopic examination did not, however, reveal any special type of cell.

The left kidney was wholly wanting with its capsule. The organ of the right side was more than of the average size. No sign of the left ureter existed in connection with the bladder, which was large and flabby, but otherwise normal.

The uterus was bifid; the separation between its lateral halves extending almost to the lower extremity of the organ. The os uteri was single. Just between the posterior lip of the os uteri

4301 Kidney of an infant
1961
119
4
Pres by Dr Hunsdale

~~4323 Kidney~~

1964
119
4
4306.00 Kidney.
Linear rupture of kidney protected by capsule.
Also a small anemic infarct.
(see Specimen of spleen No. 135).
Presented by U.S. Base Hospital No 10.

40
4324 Enlarged Fungus - Kidney.
1998
119
3.
Pres. by Mr. Mütter

4306.00 Kidney. Linear rupture of kidney protected by capsule. Also small anemic infarct. (See specimen of spleen No. 135)
Presented by U.S Base Hospital No. 10





there was a little transverse bridle of mucous membrane, like a perforated valve; the woman had been been confined four times.

Presented at the meeting of the Phila. Path. Soc'y. April 22nd, 1861. Vol. 2 p. 99

Presented by Dr. J. H. Packard.

4302 -- KIDNEY; LOBULATED.

1963
119
4

4320 small granular Kidney. Nephritis. Presented by Dr. F.A. Packard

4321 -- KIDNEY; NEPHRITIS; ACUTE.

1963
119
4

Section of a kidney showing apparently acute Bright's disease. A large white kidney.

Presented by Dr. Isaac Hays.

4322 see Vol II page 49

4328 -- KIDNEY; CHRONIC INTERSTITIAL NEPHRITIS. Missing

4329 Kidney. Page 53 - Fatty " Small Granular Kidney. Dale Bevan C.

Presented by Dr F.A. Packard.

4324 -- KIDNEY; SUPPURATIVE PARENCHYMATOUS NEPHRITIS.

1963
119
4

The kidney is large and the medullary portion and portions of the cortical portion have evidently undergone an inflammatory and suppurative process.

Presented by Dr. Mutter.

4326 Tubercular Kidney
1968
119
4
Pres by D Knisdale

4324.50 Scrofulous ulceration of Kidney
Presented by Dr. Mütter



(13)

4324.10 -- KIDNEY; PYELO-NEPHRITIS.

1966
119
4

The kidney has been opened and shows suppurative degeneration of the parenchyma at various points. The ureter is thickened and obstructed.

Presented by Dr. Mutter.

4324.20 -- KIDNEY; PYELO-NEPHRITIS.

2013.
119
4

The kidney is very much enlarged. The parenchyma is softened and ulcerated. Section shows large cavities from which the pus has been allowed to drain away. The cortical as well as the medullary portion has undergone suppuration. There has also been a certain amount of perinephritis; the capsule is quite adherent and hangs in shreds. The kidney is 15 cm. long.

Presented by Dr. Mutter.

4324.30 Pyelo-nephritis.
1967
119
4
.05

4328 Page 45 Missing

4328 -- KIDNEY; GRANULAR DEGENERATION and PERINEPHRITIS

The kidney is of about the natural size. Its surface is rough and shaggy.

Presented by Dr. William Pepper.

2000
119
4

4322 see Vol II page 45
~~4328.~~10 -- CHROMIC INTERSTITIAL NEPHRITIS.

4329 ~~Small granular Kidney.- Nephritis~~ Missing

2003 ~~Pres. by Mr. F. A. Packard.~~

119

4.

4332 10 Kidney:- Calculus.

2021. Pres. by Mr. Mütter

120

2.



(X)

4329 -- KIDNEY; FATTY.

2002

119

4.

The pelvis of the kidney is loaded with fat. Section of the organ shows large masses of fat invading the cortical portion.

From a man aet. 75 yrs. who suffered for many years from enlarged prostate and contracted bladder, who died after an attack of retention of urine thought to have resulted in rupture of the bladder.

(See G.) Also:

Boston Medical and Surg. Jour. Oct.1, 1885.
113: 323-324

Presented by Dr. J. L. Stewart,

Erie, Penna.

4332 -- KIDNEY; CALCULUSIN THE PELVIS.

2001

Path

119

4.

The kidney is from a child; the calculus, nearly one centimeter in diameter lies in the pelvis of the kidney. The kidney is very large and lobulated.

Presented by Dr. Mutter.

2020.

120

2.

4332.20 -- KIDNEY; CALCULI IN THE PELVIS.

Two calculi, of a light brown color and rough surface, lie imbedded in the pelvis of the kidney. The larger is cylindrical and has a long diameter of 3 cm., a thickness of 1 cm. It is partly encysted. The second calculus, about 1.5 cm.

in diameter is seen in the upper portion of the pelvis. The surface of the kidney is irregular; the capsule was evidently adherent.

Presented by Dr. Mutter.

4332.30 -- KIDNEY; CALCULI.

2019
120
2

There is an anormous calculous mass in the pelvis; smaller calculi are seen near the cortex. This large calculus is a very light color, rough surface and irregular shape. It is apparently friable. The base of the calculus is directed toward the ureter. Smaller calculi about one centimeter in diameter are distributed along the periphery. The capsule probably did not readily strip; the surface is shaggy.

Presented by Dr. Mutter.

2018 4332.40 -- KIDNEY; CALCULI IN THE PELVIS.

120
1.

There is a large calculus apparently of 2 cm. diameter imbedded in the pelvis. It is of a light color and generally smooth outline. Several smaller calculi are seen in the pelvis and periphery. The external surface of the kidney is irregular.

Presented by Dr. Mutter.

4335 ~~Scrofulous Ulceration of Kidney~~
2024 ~~Pres. by Dr. Mütter~~
120
2.

4337.10 Missing Kidney and Bladder. Kidney much
2025 degenerated and Bladder walls thickened
120
2.



(18)

4332.50 -- KIDNEY; CALCULI IN THE PELVIS.

2017 Copy
120
1.

A very large calculus about 7 cm. in length, and 4 cm. in its greatest breadth, lies imbedded in the pelvis. The surface of the calculus is white, excepting at the expanded portion, which is black in portions. The surface is smooth, excepting for certain prominences at the smaller end.

Presented by Dr. W. Pepper.

4334.4 G. 16 -- FOETAL KIDNEY. HYDRONEPHROSIS.

2023.
120
2.

The organ is about 12 cm. in diameter, and is globular. The ureter was imperfect, resembling a cord; no place of its origin can be seen; neither is it apparent at what point the vessels entered. The kidney has been stuffed with hair from a still-born child.

Presented by Dr. Hunt.

2016 4334.10 Hydronephrosis; adult aged 45
120 Sac contained 1 quart of fluid. Laparotomy. Recovery } Presented by Dr R. Stansbury Sutton 1893.
1.

4335. -- KIDNEY; "SCROFULOUS ULCERATION."
2024

Missing

The kidney is large, and presents irregularities in the pelvis; the epithelium is roughened, and at some points seems to have presented the appearance of an ulcer.

Presented by Dr. Mutter.

4339. -- KIDNEY; CYSTIC.

The kidney is small, contracted, and contains several cavities having a smooth surface, and separated from each other by thick septa. The capsule was apparently adherent, and its surface very irregular.

Presented by Dr. Mutter.

~~4339.10 -- G.7 KIDNEY; CONTRACTED AND CYSTIC.~~ destroyed

The cysts approach closely the capsule; they have a diameter of about one centimeter.

Presented by Dr. Mutter.

4339.20 -- KIDNEY; CONTRACTED; CYSTIC.

The kidney is quite small. It contains near one extremity a large cyst.

Presented by Dr. Wm. Pepper.

4339.30 -- KIDNEY; CYSTS.

Several large cysts have been formed at the expense of the kidney structure. The surface is very irregular and the capsule adherent.

Presented by Dr. Mutter.

Case 4339.35 1973-119-5

Cystic Kidney; with calculi.

From a case of Multiple Cystoma of the liver and kidney.

Presented by Dr John B. Roberts.

A GERMAN woman, fifty-six years of age, was admitted to the Woman's Hospital on October 2, 1893. For ten years she had noticed a swelling in the right side of the abdomen below the ribs, which for about one year had been somewhat painful. She had always been a healthy woman and had borne seven children. The menopause had been established ten years previous to her admission. One week before entering the hospital she began to suffer with dyspnœa and cough, accompanied by constipation and fever.

Physical exploration of the chest by the hospital physicians showed some dulness over the bases of both lungs posteriorly, with prolongation of expiration and some mucous râles. The vesicular murmur was high-pitched over portions of the dull area. The heart's action was rapid and excited. The pulse was 76, the temperature 101.8°. The frequency of the respiration, however, was not recorded; but breathing was rapid and labored. The pulse was somewhat intermittent and was irregular in rate. In the abdomen was discovered a large mass occupying the greater part of the right hypochondriac and lumbar regions. The tumor was irregular in outline and near the middle line presented a particularly marked elevation, which was elastic on pressure, and gave the examiner the impression that it was a cyst. Percussion dulness was found in the right flank, tympanitic resonance in the left; but there was bulging in both regions. The intestines seemed to be pushed to the left side of the abdomen and were distended with gas. The urine was acid, of a dark color, and had a specific gravity of 1020. Its chemical and microscopical examination was negative. The woman was not jaundiced, and her bowels were moved freely after the administration of Epsom salt and an enema. There was no bulging in the vault of the vagina and the mass in the upper abdomen was not palpable by vaginal touch.

Under treatment directed to the pulmonary condition the cough improved, the mucous râles nearly disappeared and the expectoration became free. The patient, however, still found it difficult to lie flat upon her back, and usually was propped up in bed to make her respiration more easy. I repeatedly examined the woman during the first three weeks of her stay in the hospital, and became quite convinced that the tumor was a cystic growth involving the liver, and that a portion of her dyspnœa was the result of upward pressure of the abdominal mass.

probable that I punctured healthy liver tissue. The oozing continued while I was occupied in other steps of the operation, and was finally controlled, after a number of cysts had been emptied, by scooping out the clots and packing the deep cyst with iodoform gauze. Altogether I must have evacuated the contents of about three large cysts and five or six smaller ones, puncturing them with a knife thrust in various directions through the intervening cavities that had been laid open. The fluid in all of them was limpid. On the left wall of and within the first cyst opened was one of the cysts growing inward, already mentioned. When I punctured this with a knife I heard a whistling noise, as though air had escaped from it. No fluid appeared to be in it, and at first I thought I must have opened the intestine. Careful exploration, however, with my finger showed the cyst to be empty and to have no perceptible opening in its wall except that made by the knife and through which I had introduced my finger. It seems impossible to believe that this cyst contained gas only. A careful investigation of its interior with my finger failed to disprove this

4339.35
1972-119-5

Cystic Kidney; milk calculi.

From a case of Multiple Cystoma of the liver and Kidney.

Presented by Dr John B. Roberts.

to the right of the suspensory ligament. I discovered, by inserting my hand into the peritoneal cavity, that both the right and the left lobes of the liver, as far as I could feel, were occupied by numerous cysts, varying in size from an inch to four inches in diameter. The liver, by reason of these cysted growths, was enormously enlarged and the suspensory ligament extended almost to the umbilicus because of the growth upward and forward of the upper surface of the liver. I could feel the gall-bladder beneath the enlarged right lobe, and by palpation discovered that it contained an irregular calculus. There was a little ascitic fluid in the peritoneal cavity. The cysts seemed not to communicate with each other but to develop independently throughout the substance of the organ.

The prominent cyst over which the incision was made was stitched to the parietal peritoneum by a continuous suture, because I believed that it was wise to delay its puncture until adhesion had taken place with the anterior abdominal wall. At the left side of the cyst above, the sutures were carried through the tissues of the suspensory ligament of the liver instead of being inserted into the cyst-wall proper. This procedure left an opening in the belly wall, occupied by the surface of the cyst, about three inches long and two inches wide. The lower part of the incision was closed by three interrupted silk sutures, so that the peritoneal cavity at this point might be kept closed. A dry antiseptic dressing was applied, and the patient was put to bed and treated as other cases of abdominal section are managed.

The diminution of intra-abdominal pressure produced by the escape of abdominal fluid and by the bulging forward permitted by the operation gave considerable relief to the dyspnœa. The contour of the abdomen somewhat changed and the outlines of the tumor were better defined on the left side. The patient was now able to lie down. Some clear serous fluid escaped from the uppe



portion of the opening where the liver was stitched to the belly wall. This coagulated from boiling and possibly came from the peritoneal cavity, not from any puncture in the cyst made by the needle. I was rather uncertain, however, as to the exact source of this leaking.

On October 27th I laid open the cyst without giving the patient ether. As I was about to begin operation her coughing and straining caused the ejection of a jet of serum from one of the suture punctures in the abdominal wound close to the umbilicus. This was evidence that there was some peritoneal dropsy and that the intra-abdominal tension due to the growth was great. The uncovered surface of the cyst was coated with a layer of plastic lymph of a yellow color.

A puncture was made with a trocar into the wall of the cyst and several ounces of clear fluid escaped. Into the cyst cavity thus emptied were projecting one or two distended cysts three-quarters of an inch to an inch in diameter. These were punctured and gave exit to limpid fluid. Directly behind the large cyst first opened appeared to be a second cyst. This I punctured with a knife and evacuated several ounces of fluid. I thought I detected with my finger fluctuation of a similar cyst behind the second cavity, though I could scarcely touch the posterior wall of this second cyst with my finger introduced through the first cyst and through the orifice between the two cysts. The sense of fluctuation was so similar to that given by the cystic tumors already punctured that I finally thrust a long trocar into the posterior wall of the second cyst. This operation was done, of course, in the dark. Nothing but fluid blood escaped, and it is, therefore, probable that I punctured healthy liver tissue. The oozing continued while I was occupied in other steps of the operation, and was finally controlled, after a number of cysts had been emptied, by scooping out the clots and packing the deep cyst with iodoform gauze. Altogether I must have evacuated the contents of about three large cysts and five or six smaller ones, puncturing them with a knife thrust in various directions through the intervening cavities that had been laid open. The fluid in all of them was limpid. On the left wall of and within the first cyst opened was one of the cysts growing inward, already mentioned. When I punctured this with a knife I heard a whistling noise, as though air had escaped from it. No fluid appeared to be in it, and at first I thought I must have opened the intestine. Careful exploration, however, with my finger showed the cyst to be empty and to have no perceptible opening in its wall except that made by the knife and through which I had introduced my finger. It seems impossible to believe that this cyst contained gas only. A careful investigation of its interior with my finger failed to disprove this

4339.35
1973-119-5

Cystic kidney; with calculi.

From a case of Multiple Cystoma of the liver and kidney.

Presented by Dr John B. Roberts.

to the right of the suspensory ligament. I discovered, by inserting my hand into the peritoneal cavity, that both the right and the left lobes of the liver, as far as I could feel, were occupied by numer-



supposition. I am forced to believe that it was filled with gas but cannot understand the occurrence. It was so deep that I could make no examination with the eye.

After some eight or ten cysts of various sizes had been opened by incising the walls between them, I cut away the anterior wall of the first cyst, making the opening into it correspond very nearly with the aperture into the parietes of the abdomen. This excision opened the peritoneal cavity at the upper and left portion of the wound where the suspensory ligament of the liver was attached to the left side of the abdominal incision. It will be remembered that at the first operation the suspensory ligament was seen and stitched to the belly wall in order to assist in shutting off the surface of the liver from the peritoneal cavity at the seat of proposed secondary operation. The opening into the peritoneal cavity, made by the unexpected cutting through the suspensory ligament, was closed by a continuous silk suture. I then excised for examination a portion of the tissue which constituted the walls of several contiguous cysts in the bottom of the deep cavity in the liver made by evacuating the several cysts. An active venous hemorrhage occurred from a vein which was opened by cutting through the inter-cystic wall at a place where it was rather thick. The bleeding vein was compressed with pedicle forceps and afterward surrounded by two silk sutures carried through the tissues in a circular manner by a needle. This manœuvre stopped the bleeding. The irregular cavities left by the evacuation of the cysts' contents were thoroughly washed with hot water and the whole space packed with iodoform gauze. A separate piece of gauze was pushed firmly into the deep cyst, which was being filled, as previously detailed, with blood from the wound in the liver behind. The patient showed comparatively little shock during the operation, reacted promptly, and has been for ten days in a satisfactory condition. She can lie flat upon her back, the respiration has been much less impeded, and no evidences of sepsis or peritonitis have occurred. The packing was not removed until the ninth day, and a new gauze packing was then adjusted loosely. Twelve hours later a secondary bleeding occurred from the deep cyst, and iodoform gauze was again *tightly* packed into it. The fluid removed from one of the cysts was examined microscopically for echinococcus hooklets, but none were found. Chemical examination showed it to be albuminous—a condition opposed to the theory of the case being one of multiple hydatid cysts. The amount of serous fluid evacuated from the cyst opened was difficult to estimate, as the blood from the deep wound of the liver became mixed with the cystic contents. The fluid and blood together measured two quarts.

I have made only a hasty search of the literature of hepatic cysts;



but have not been able to find as yet a case resembling this except one reported by Hayward.[1] His patient was a girl six and a half years, who died after operation for multiple small cysts apparently connected with the anterior surface of the liver.

Cases of cystic degeneration of the liver and similar disease of the kidneys in the same patient have been observed and reported by Bristowe, Chantreuil, Courbis, Gayraud, Lataste, Pye-Smith, Leboucher, Wilks, and perhaps others. The London Pathological Society's *Transactions* contain some interesting discussions on the subject. The cases whose reports I have thus far seen seem to differ materially from the case reported. Most of them seem to have been instances of very small cystic tumors, or more like a true cystic degeneration. Victor Leblond,[2] in his recent work, says that serous cysts of the liver, that is, non-parasitic cysts, are very rare, that their existence is denied by some authors, that they are small and difficult to recognize and are apt to be associated with polycystic kidney. Mayo-Robson gives in his article on "Surgery of the Liver and Gall-bladder,"[3] an interesting account of cysts of the liver.

In my case here reported the condition of the kidney is unknown, for the patient is still living and apparently is convalescent. The cysts, however, certainly contained serous fluid and are quite large.

Further Note.—The patient seemed to be slowly convalescing, when a large bedsore formed over the sacrum, notwithstanding the fact that she had been kept on a water bed since before the operation. The temperature was somewhat elevated, but not markedly so. On November 11th, three weeks after operation, she died suddenly and unexpectedly.

Autopsy Notes.—Cyst wall found to be firmly united to abdominal wall at edges of wound as approximated at the time of operation. Extensive adhesions of the peritoneum found over the entire lateral and posterior surfaces of the liver.

The liver itself was greatly enlarged, weighing 11½ pounds, and was riddled throughout by cysts. One large cyst, opened post-mortem, in the right lobe of the liver was found to contain about a pint of yellowish pus-like fluid. The solid portions of the liver resembled the condition called "nutmeg liver." A stone was felt in the neck of the gall-bladder, and the gall-bladder itself was greatly attenuated as a result of the pressure induced by development of the cysts. The spleen was somewhat enlarged and contained a whitish spot of softened tissue resembling a gummatous

[1] Sajous' Annual of the Universal Medical Sciences, 1892, vol. i., C. 33; abstract from Australasian Medical Gazette, September, 1891.
[2] Diagnostic et Traitement des Abcès au Foie, 1893, p. 62.
[3] British Med. Journal, April 15, 1893, p. 787.

4339.35
1972-119-5

Cystic kidney; with calculi.

From a case of Multiple Cystoma of the liver and kidney.

Presented by Dr John B. Roberts.



to the right of the suspensory ligament. I discovered, by inserting
into the peritoneal cavity, that both the right and the left



tumor. This was incised for examination. Both kidneys were greatly enlarged and riddled with cysts. The uterus and ovaries were found atrophied and non-adherent.

The pleural cavity of the right side was full of serous fluid. The base of the right lung posteriorly was completely consolidated. The left lung showed small areas of consolidation at its base and posteriorly, but was for the most part crepitant. There was no fluid in the pericardial sac.

The heart was pale, very soft and flabby and of normal size. The right ventricle was completely filled by a soft chicken-fat clot. The left ventricle was similarly occupied by a clot which extended into the aorta. The valves were perfect.

4939.38 X

Cystic Kidney. Presented by Dr. W. J. Taylor. 1974-119-J (18)

4339.40 X -- KIDNEYS; CYSTIC, WITH PHOSPHATIC CALCULI.

1975
119
J

The kidneys have undergone pronounced cystic degeneration. The pyramids and cortical structure are nearly destroyed. The remaining tissue is soft and easily torn, in some places seeming ready to break down. The cysts contained pus. Seven large phosphatic calculi, having sharp points, are seen encysted in one kidney, and ten in the other.

From Mrs. E.R., aet 49 yrs. Ten years before death she voided with the urine several small calculi. Five years previous, she began to pass from three to four quarts of urine daily, heavily loaded with pus and blood. Death occurred from gangrenous Diphtheritic sore throat.

Post Mortem the bladder was found but little altered. The uterus well supported and free from irritation. The ovaries healthy, but atrophied. Kidneys as above described.

Presented by Dr. J. Cheston Morris.

4340. X -- KIDNEY; EMBOLISM.

1976
119
J

From a patient aet. 30 yrs., who had ulcerative Endocarditis; treated Oct., 1870, at the Philadelphia Hospital. See Cir. 14.

Presented by Dr. Pepper.

Red. 4346. Kidney and ureter. Distention of the
2007. Ureter. The ureter is larger than the
119 Kidney. Presented.
5

4357. -- KIDNEY; CANCER.

2008
119
5
Path.

The kidney is large and nodulated. The cancer nodules are smooth, and are corroded by the capsules of the kidney, so that they do not present any color different from the intervening kidney structure.

From a man aet. 20 yrs., of good family history, and without cancerous cachexia and oedema. The autopsy revealed a large tumor occupying a part of the anterior mediastinum, and compressing the upper left lung. The tumor had ~~bosses~~ bases, and was adherent to the sternum and cartilages of the ribs; on section it was of a uniform white appearance. The pericardium was more or less roughened by organized fibrinous deposits. The heart itself was in a normal condition. Both kidneys were enlarged, and filled with spherical masses, varying in size from a pea to a cherry, and in structure closely resembling the thoracic tumor. The other organs

4357.[10] Removed by Laparotomy from patient 39 years old. Had a pain in left side for four years. In Feb. 1892, a lump about the size of a hens egg appeared, grew to present size gradually. Two months before operation, pain was confined to bed, suffering great pain. Patient made a good recovery. The tumor on removal weighed five pounds.

2031
120

pres. by Dr. R. L. Sutton

4357. -- KIDNEY; CANCER.

2008
119
5
Pedc

The kidney is large and nodulated. The cancer nodules are smooth, and are corroded by the capsules of the kidney, so that they do not present any color different from the intervening kidney structure.

From a man aet. 20 yrs., of good family history, and without cancerous cachexia and oedema. The autopsy revealed a large tumor occupying a part of the anterior mediastinum, and compressing the upper left lung. The tumor had ~~bosses~~ bases, and was adherent to the sternum and cartilages of the ribs; on section it was of a uniform white appearance. The pericardium was more or less roughened by organized fibrinous deposits. The heart itself was in a normal condition. Both kidneys were enlarged, and filled with spherical masses, varying in size from a pea to a cherry, and in structure closely resembling the thoracic tumor. The other organs were not examined. Microspocic sections revealed the usual appearances of cancer. The cancer of the kidneys did not interfere with the function of those organs.

Trans. Coll. Phys. Phila., Vol.1. New Series, p. 100

Presented by Dr. Wm. Pepper, Sr.
May 6, 1851

4357.10 Kidney; cancer.
Weight 5 lbs.
Presented by Dr R. Stansbury Sutton.

4357.1 -- KIDNEY URETERS AND BLADDER. CANCER OF THE URETERS.

The Kidney is large; the ureters are cancerous The bladder appears normal.

From a patient in the Philadelphia Hospital.

Presented by Dr. William Pepper.

4375. -- KIDNEY; ENLARGED PELVIS.

The kidney is of normal size. The pelvis is very large and apparently of one-third the bulk of the organ. The ureter which is attached is large but not greatly distended. It is impossible to say from inspection what was the occasion of the enlargement of the pelvis.

Presented by Dr. Mütter.

4400. -- ~~CRYPTOTOR CHID~~, from a boy aet. 18 who has epilepsy.

Removed and presented by Dr. William Hunt.

Specimen lies in the jar.

4405. -- INJURY OF THE TESTICLE. FATTY DEGENERATION; ATROPHY; EPILEPSY FROM PERIPHERAL IRRITATION; CURE BY EXCISION OF THE TESTICLE.

Case of Joseph Johnson, Port Norris, N.J. Epileptic convulsions came in 60 days after a severe injury in which the testicle was driven into the inguinal canal. Convulsions daily for 8 or 9 months, 4 to 25 daily. No attack since the operation, 12-29-88. Specimen is suspended in the jar.

Removed and presented by

Dr. Wm. Hunt.

Case reported by Dr. Guy Hinsdale, Am. Jour. Med. Sci. 97:587-592. ~~Phila. Neurological Soc.~~, March, 1889.

4418.4 -- TESTICLE; ATROPHY WITH VAGINAL HAEMATOCELE.

2043
120
5

The tunica vaginalis has been laid open, disclosing a somewhat atrophied testicle. The centre of the testicle appears softened, and of a spongy texture. The tunica vaginalis is not thickened, but is distended.

Presented by Dr. J. H. Packard.

4418.10 -- TESTICLE; ATROPHY WITH VAGINAL HAEMATOCELE.

2044
120
5

The testicle is smaller than in the previous case, and the tunica vaginalis more distended. The latter is thickened, and its serous surface presents several discolored areas, due to the presence of extravasation. The specimen is 9 cm. long.

Presented by Dr. J. H. Packard.

4420. -- TESTICLE; CHRONIC ORCHITIS.

2045
120
5
Pat.

The testicle is enlarged, having a length of 8 cm. Section shows an organ of firm consistence, containing caseous bodies of a yellowish color, darker than the tissue of the gland itself.

Presented by Dr. W. Pepper.

4420.10 -- TESTICLE; CHRONIC ORCHITIS.

2046
120
5
Pat.

The testicle (testicle) is greatly enlarged. Section shows a yellowish homogeneous caseous substance in the body of the testicle. This body greatly enlarges the testicle, occupying two-thirds of the cross-section, and being situated superiorly. The testis is 9 cm. long.

Presented by Dr. Mutter.

4437. -- TESTICLE; FIBROMA.

2047
120
5
Pat.

The testicle is enormously enlarged, having a length of 9 cm. Cross section shows a firm, dense tissue of uniform color. The tumor is encapsulated in the albuginea; its surface is nodulated.

Presented

2048
120
5

4437.10 -- TESTICLE. FIBROMA.

The testicle is enormous, having a long diame-

ter of 11 cm. It is invested by the tunica albuginea, which on section is seen to send long and firm prolongations of fibrous tissue into the body of the tumor. The tumor is dense; at the upper portion are two small cysts.

4437.20 K Presented see Vol II Page 104

4438.10 A -- LEFT TESTICLE; SARCOMA.

2049
120
Rud. 5

The testicle is enlarged, being about 10 cm. long. The shape is globular, with smooth surface, excepting on one side, where the skin had evidently been ulcerated. There is a cavity in the interior about 3 cm. in diameter.

Removed from W.H.C., aet 50. Disease commenced 3 1/2 years previously without any known cause. No syphilis. In February, 1866, the testicle became sore, and later was lanced by Dr. Child. Eight ounces of pus escaped. It closed, suppurated, and discharged five or six times. Right testis healthy. An enlarged gland occupied the left groin; the ~~spermatic~~ spermatic cord of the left side was thick and hard.

Presented by Dr.W.L.Atlee.

4438.20 A -- TESTICLE; SARCOMA.

2050
120
5

The testicle is enlarged, its length being 11

cm. The surface is not nodulated, but is shaggy from the attachment of the albuginea. Section shows an excavated center. There are numerous cavities invested with fibrous walls. The periphery of the testicle is made up of a thick laminated fibrous layer, the hypertrophied tunica albuginea.

The specimen has been injected with red lead.

Presented by Dr. Mutter.

4438.30 -- TESTICLE; SARCOMA.

2051
120
5

The testis is enlarged; it is of a generally smooth exterior. Section shows a large cavity in the growth.

Lyons, 1847.

Presented by Dr. Mutter.

4438.40 -- TESTICLE; SARCOMA.

2052
120
5

The testis is greatly enlarged; it has a length of 10 cm. It is of globular shape, and smooth exterior. An opening in the wall shows a softened interior.

Presented by Dr. Mutter.

2053
120
5

4438.50 -- TESTICLE; SARCOMA.

The testicle is enlarged, and of a flattened

shape. The exterior is rough, and presents several rounded prominences which are cystic.

Presented by Dr. Mutter.

4438.60 -- TESTICLE; SPINDLE CELL SARCOMA.

1977
119
6

The testicle is enlarged, having a length of 6 cm. The surface is smooth. Gross section shows a structure of nearly uniform color.

Microscopic section showed the tumor to be Spindle cell Sarcoma.

Presented

4438.70 -- TESTICLE; SARCOMA.

1978
119
6

The testis is not much enlarged, having a length of 5 cm. The skin was evidently broken, and openings are seen in the specimen through which discharges may have escaped. Section shows a spongy texture and shaggy surface.

Presented by Dr. Mutter.

4438.80 -- TESTICLE; SARCOMA.

1979
119
6

The testicle is very slightly larger than normal; it was apparently ulcerated, one side being shaggy and showing yellowish masses in the gland.

Presented by Dr. Mutter.

4446. See Vol II page 109
~~4438. 90~~ -- TESTICLE; CYSTIC; TRAUMATIC ORIGIN.

1980
119
6

The testicle is enlarged, and contained numerous cysts.

From R.S., aet. 28. Twenty-one months previously was struck by a plank on the left testicle and sternum. Necrosis of the bone and exfoliation followed. The testicle became enlarged, swollen, and subsequently an abscess formed and pointed. The same thing happened five times afterward. The testicle became enlarged, hard, lobulated with an opening anteriorly from which was constantly exuded a ropy, yellow liquid like synovia mixed with pus. The testicle was successfully removed by Dr. John H. Packard.

Presented by Dr. Packard.

4439. -- TESTICLE; SCIRRHUS.

2054
120
6

The diseased testis enclosed in the tunica vaginalis has a length of 9 cm., and a breadth of 6 cm., and is of oval shape. The surface of the tunic is smooth, and on the surface the finer vessels are seen to be injected. The tumor has not been exposed.

Presented by Dr. Mutter.

~~4439.36~~ Testicle: Cystic
1983
119
6 ~~Presby Dr Mutter~~

4437.20 IX see Vol II Page 89
~~4439.36~~ Multilocular Cystic Tumor of the
2847 Testicle. Removed June 1895.
119 Presby Dr. W. S. Rodman.
5



4439.10 IX -- TESTICLE; SCIRRHUS.
1981
119
6

The testicle is enlarged, having a diameter of 8 cm. Section shows alveoli of fibrous tissue enclosing bodies of darker color.

The arteries have been injected with red paint.

Presented by Dr. Mutter.

4439.20 IX -- TESTICLE; SCIRRHUS.
1982
119
6

The organ is enormously enlarged, having a length of 13 cm., and a breadth of 10 cm. Vertical section shows a firm mass with small fibrous alveoli.

The tunica vaginalis is adherent, and is not ulcerated.

Presented by Dr. Mutter.

4439.35 IX -- TESTICLE; CYSTIC AND CANCEROUS.
1984
119
6

Presented by Dr. Mutter.

4439.37 IX -- TESTICLE; CANCER.
1985
119
6

Marked "Fungus, Lyons, 1847."

Presented by Dr. Mutter.

4446. X see Vol II page 101
4446.05 X Testicle - cystic. Presented by Dr. Mutter.
4447. X see Vol II page 110



(128)

4439.40 X -- TESTICLE; SCIRRHUS.

2004
119
6

The testicle is enlarged, having a length of 9 cm. The surface is smooth and nodulated. Sections shows a dense tissue, with fibrous bands running in various directions. The tissue is not softened, but firm.

Presented by Dr. Mutter.

4439.50 X -- TESTICLE; SCIRRHUS.

2005
119
6

The testicle is moderately enlarged, and has been removed, together with a portion of the scrotum. The surface is nodulated, and the tumor is apparently of very firm consistence.

Presented by Dr. Mutter.

4453 X
~~4440~~. -- DOUBLE SPERMATIC CYST.

2006
119
6

It is very large, being 16 cm. long, and 8 cm. thick. The fluid contained spermatozoa. The testicle was degenerated and softening.

From a man aet. 63. Duration of growth 51 years. Stationary for many years.

Presented by Dr. J. Ewing Mears.

2055
120
6

4441. X Testicle.
Gumma; chronic syphilitic Orchitis with fungation
Presented by Dr. O. Horwitz.

4456. X -- TESTICLE, EPIDIDYMIS AND TUNICA VAGINALIS.
VAGINAL HYDROCELE.

2056
120
6

The epididymis is slightly enlarged; the tunica

4460. 1:0 Spermatic cord; arborescent Lipoma.
2060
120
6

4447. see Vol II page 108
~~4461~~. Jno. Russell 56. Encysted Hydrocele of Cord
2848 High up at Int. Ring. On right side Removed
119 by Prof. O'Neille Horwitz given by same



vaginalis is distended, and is opened so as to display the interior of the cavity.

Presented by Dr. Mutter.

4456.10 -- TESTICLE AND TUNICS; VAGINAL HYDROCELE.

2057
120
6

The testicle is enclosed with the fluid in the sac.

Presented by Dr. Wm. Pepper.

4457. -- TESTICLE; VARICOCELE; INJECTED.

2058
120
6

A red injection shows well the distended vessels.

Presented by Dr. Mutter.

4460. -- SPERMATIC CORD; ARBORESCENT LIPOMA.

2059
120
6

The specimen when removed from the body measured 45. cm., and weighed 382 grammes. A microscopic examination made by Dr. W. A. Edwards, shows that the enormous increase in size is due to the formation of arborescent lipoma. It sprang primarily from the serous surface of the epididymis and spermatic cord, finally converting both these structures into pure lipoma. The smaller masses and membranes festooned along the edges of the growth are essentially of the same pathological structure. The

blood vessels in the masses are seen to have very low grade walls, and are not by any means the well-developed vessels that we would expect to find in the normal omentum.

From a patient of Dr. John L. Atlee's, aet. 46, who had a congenital left inguinal hernia. Strangulation of the bowel had occasionally happened, but the hernia had always readily been replaced. On one occasion strangulation took place, and at the end of thirteen days herniotomy was performed. A large mass of omentum was raised from the scrotum, and about 12 cm. of the ileum firmly strangulated, and of a dark mahogany color, but with no ash-colored spots. From the ring proceeded a cord as thick as a lead pencil for about three inches; it then became much thicker, and highly vascular, resembling the omentum which had already been removed, forming a large mass lying in the bottom of the scrotum; in some places five or six centimeters thick with many smaller lumps extending down the mass, and constituting the spermatic cord and epididymis. The testicle was wasted, soft and firmly attached to the bottom of the cavity.

The mass was removed, after tying at the ring above and at the testicle below. The patient died within twenty-four hours. Food had not been retained for thirteen days.

See Amer.Jour.Med.Sci., Jan'y, 1883. 85: 117

Presented by Dr. John L. Atlee.

4506. Cyst of Gland of Bartholini.
2066 Removed Jan. 7. 1898. Size 2" x 1
121
1.

Presented by Dr. F. W. Dryspale

4511. -- FIBROMA OF THE VULVA.

2067.
121.
1.

The tumor is of nearly spherical shape, and is 10 cm. long. The tissue is dense, and evidently cut with difficulty. The surface is wrinkled, and rather irregular. It was probably not pedunculated.

Presented by Dr. Mutter.

4511.10 -- FIBROUS TUMOR OF THE VULVA; PEDUNCULATED.

2068.
121.
1.

The tumor is about 8 cm. broad by 7 cm. long. The exterior is deeply wrinkled and fissured. The growth was evidently firm. It had a pedicle 6 cm. long, and 2 cm. in diameter, in which a whalebone has been inserted to keep it upright.

From a mulatto woman, a prostitute, who had the tumor removed because of its obstructing coition.

Presented by Dr. Mutter.

4511.20 -- FIBROMA OF THE VULVA; PEDUNCULATED.

2069
121.
1.

The tumor is very large, measuring 11 cm. in breadth, and 9 cm. long. The pedicle is 3.5 cm. long, and 1.5 cm. in diameter. The tumor is corrugated, bilobed and firm.

From the labium majus.

Presented by Dr. Mutter.

4540. X
2073.
121.
1.

Destroy? 33-4

4601. X Hysterectomy.
2075
121
1.
Pres. by Dr. Drysdale.

4601.10 X Hysterectomy
2076.
121
1.
Pres. by Dr. C. P. Noble.

4601.30 X Hysterectomy

4601.40 X Hysterectomy Presented by Dr. Drysdale



(32)

2070 4511.25 X Fibroma of Left Labium majus.
121 Duration 5 yrs Wright 5 ½ lbs. Removed and presented
1. Patient aged 45. by Dr R. Stansbury Sutton 1893

4511.30 X -- FEMALE GENITAL ORGANS; FIBROMA OF THE VULVA
2071 AND ANUS.
121
1.

Attached to the left labium minus is a fibrous tumor about 3 cm. in diameter, attached by a short pedicle. Similar growths of small size are seen on the opposite side and at the anus. The meatus urinarius is apparently placed about 4 cm. within the vagina; at that point a probe has been introduced, and is seen to emerge from the posterior portion of the specimen, anterior to the very long cervix uteri. The uterus is small, and the ovaries normal.

Presented.

4512. X -- EPITHELIAL CANCER OF THE CLITORIS.
2072.
121.
1

An enormous cauliflower growth occupies the site of the clitoris and adjacent tissues. It is symmetrical, and has a diameter of about 8 cm. It is a perfect example of this form of cancer. The tufts are large, and have short, strong pedicles.

Presented by Dr. Corse.

2074 4601, X Hysterectomy, vaginal " " Geo. E. Shoemaker.
121. Case of Mrs. Horn.
1.

4612. X -- UTERUS SHORTLY AFTER DELIVERY.
2077
121
2

The walls are about 1.5 cm. thick. The uterus has a breadth of about 10 cm.

Presented by Dr. Mutter.

missing

4612.40 Uterus shortly after delivery. Decomposed
2083
121
2. Blood clots etc.

23

4612.10 -- UTERUS SHOWING THE EFFECTS OF CHRONIC INFLAMMATION.

2078
121
2

From the Philadelphia Hospital.

4612.20 -- UTERUS AND APPENDAGES; GRANULAR PERITONITIS.

2079
121
2.

From the Philadelphia Hospital.

4612.30 -- UTERUS; ABSCESS.

2080
121
2

The abscess was situated on the right side, beneath the broad ligament. The ovaries are healthy.

Presented by Dr. Parry.

2081 4613 Thickened endometrium from a case of membranous
121 dysmenorrhea simulating extra uterine foetation.
2 Presented by Dr. W.C. Goodell.

4617. -- ELONGATED CERVIX; UTERI; AMPUTATED.

2082
121
2

From a patient aet. 24 yrs. Menstruation regular. When the os was held on the stretch, the sound entered 11 cm. The cervix measured 6.3 cm. to the insertion of the vagina. Section was made 4 cm. above the os.

Presented by Dr. W. L. Atlee.

4624.05 Tumor of the Uterus

4624.10 Tumor of the Uterus

4624.15 see Vol II page 157.

4624.20 see Vol II page 157.

4625 Uterus showing tumors.
2084 Pres by Mr. J. H. Packard.
121
2.

4627 Seven Specimens of Fibroma of Uterus.

1st. Specimen presented by Mr. Corse.

(1.) 2087 — 4627.001 Sec. 121 Shelf 2.
(2.) 2088 — 4627.002
(3.) 2089 — 4627.003
(4.) 2090 — 4627.004
(5.) 2091 — 4627.005 Shelf 3.
(6.) 2092 —
(7.) 2093 — 4627.006 (Price)

The presentors of the 6 other specimens unrecorded.

(8.) 4627. Fibroma of the Uterus.
2115 — 4627.006
123
1.

(9.) 2116 — 4627.025 " " "
123
1.

2117 — 4627.007 " " " "
123
1

Pres. by Mr. Baldy (presented this last specimen (2117 . 123 . 1.)

4627.008 Fibroma of the Uterus.
2131
123
2

4627.009 Fibroma of the Uterus.
2177
124
Pres. by Mr. Price.



(35)

4625.01 -- G. 97. UTERUS; POLYPUS.

2085
121
2.

The polypus arises from the mucous membrane of the uterus about 1 cm. within the internal os.

From the Philadelphia Hospital.

4626. -- FIBROUS POLYPUS OF THE UTERUS.

2086
121
2.

Presented by Dr. J. Ewing Mears.

4627. -- FIBROMA OF UTERUS.

2087
121
2.

Presented by Dr. Corse.

4627.01 Fibroma of the Uterus in Situ. Presented by Dr Price.
2098
121
2

4627.02 Fibroma of the Uterus 2099 121 Presented by Dr Price.
3

4627.03 -- INTRA UTERINE CYSTIC FIBROMA.
2090 121 3
2100 121 5

Presented by Dr. G. Betton Massey.

4627.04 Fibroma of the Uterus Presented by Dr Price
2091 121 3
2101 121 5

4627.05 -- CYSTIC FIBROMA OF THE UTERUS.

2092 121 3
2102 121 5

Presented by Dr. J. M. Baldy.

4627.06 Fibroma of the Uterus. Presented by Dr Price.
2093 121 3
4627.07 " " " " Presented by Dr. "
2103 121 5
4627.08 " " " " Presented by Dr. Baldy.
4627.09 " " " " Presented by Dr. "
2104 121 5
4627.10 -- FIBROMA OF THE UTERUS.

2094
121
3

The specimen is about 6 cm. long, and 5 cm. wide. It was impacted in the pelvis.

Presented by Dr. W. L. Atlee.

(5)

460. External and Internal Genitalia

2113 Pres. by Dr. Drysdale.
121
4.



2095 4627.11 Fibroma of the uterus.
121
3. One nodule of fibroid is myoma; the capsule of the other nodule is undergoing calcareous degeneration. Presented Dec. 6th 1894. By Dr Jas. Baldy.

2106 4627.12 Fibroma of the Uterus. Presented by Dr. Noble
121
6. 4627.13 " " " " " " " " Hysterectomy

2107 Case of Sallie Brown Womans Hospital 4.11.95.
121
6.

4627.14 Hysterectomy for fibroma
2108 Presented by Dr. C.P. Noble.
121
6.

4627.15 Fibroma of the Uterus. {2109 121 6.

4627.16 Multiple Intraligamentary
2110 Fibroma of the uterus; left side.
121 Supra vaginal amputation; recovery.
6. Presented by Dr Geo. E. Shoemaker.

4627.17 Fibroma of the Uterus
2105 Presented by Dr Joseph Price.
121
5

4627.18 Remains of Uterine Multiple Fibroids;
2111 Healed by electricity. Case of Mrs M.B.G.
121
6. aet 71 yrs. Death from Brights Disease (large White Cystic Kidney) May 19, 1899.

Presented by Dr. J.M. Drysdale

4627.19 Fibroma of the Uterus. With pyosalpinx. Hysterectomy.
2112 April 20, 1897. M.G.H. Presented by Dr. Shoemaker
121
6.

~~4627.20. Uterus: - Fibroma.~~

2118
~~123~~
1

~~Mr. Atlee.~~

4627.~~29~~ Uterus and Ovaries. Uterine fibroids.

2121
123
1.

4627 21. Tumor of the Uterus.

2327.
129.
5.

Pres. by Mr. W. W. Keen.

4745.05

~~4627.22~~ Pedunculated Fibroma of both

2845
121
4.

Ovaries.

Pres. by Dr. Richard A. Cleeman.

See - Pg. 198 - Vol. II



(36)

2119
123
1.

4627.27. Three uterine fibroids. Presented by Dr W. J. Taylor

4627.20 -- UTERUS AND OVARIES. FIBROMA OF THE UTERUS.

2118
123
1

The tumor springs from the peritoneal surface, at the summit of the uterus. It has a diameter of 4 cm., is sessile and is dense. The uterine appendages are healthy. The fallopian tubes and the fimbriated extremities are well seen.

Presented by Dr. W. L. Atlee.

2120
123
1

4627.28 Uterine fibroid. Presented by S. Mears.

2114
121
6

4627.29 Uterus and Ovaries. Fibroma of the uterus.

4627.30 -- UTERUS AND APPENDAGES; FIBROMA OF THE UTERUS.

2122
123
1.

The uterus is very much enlarged, and has the appearance of the organ in the sixth month of gestation. A vertical opening shows a large fibroid tumor about 8 cm. in diameter occupying its cavity, having undergone partial decomposition; masses of it hang in shreds.

Presented by Dr. W. L. Atlee.

2123
123
1.

4627.31 Uterus and appendages. Enormous fibroid. Presented by S. Jn. Baldy.

2124
123
2.

4627.32 Uterine Fibroid.

4627.40 -- FIBROID POLYPUS OF THE UTERUS.

2125
123
2.

The specimen is spheroidal, and has a diameter of about 5 cm. No pedicle is seen. It is nodulated and apparently dense.

Removed by the ecraseur, November 8th, 1867, from a woman aet. 41, subject nearly three years to flooding. She was the mother of two children, the elder being thirteen years old.

Presented by Dr. W. L. Atlee.

~~4627.41~~ Fibroma of the Uterus.
~~2127~~
~~123~~
~~2.~~

4627.421 Two Specimens of Uterine
2129 Sec. 123 Shelf 2. Fibroids. The first presented
2130
4627.425. by Mr. T. M. Drysdale.

4627.43 Fibroma of the Uterus.
2133.
123.
2

4627.445 Fibroma of the Uterus.
2135
123
3.



2126 4627.41 Fibroma of the Uterus. Presented by Dr. J. M. Drysdale
123
2.
2128 4627.42 Fibroma of the Uterus. Presented by Dr. " "
123
2.
4627.43 Fibroma of the Uterus. Presented by Dr. " "
2130
123
2. 4627.44 Fibroma of the Uterus. Presented by Dr. " "
2134.
123
3.

4627.45 -- FIBROID TUMOR OF THE UTERUS.

2136
123
3.

The growth involves the fundus of the uterus; it is about 13 cm. in diameter, symmetrical and firm.

Presented

2137
123
3.

4627.46 Fibroid tumor of the uterus; haematoma and appendages. Presented by Dr Baldy.

2138
123
3

4627.47 Uterine Fibroid " " " "

2139
123
3

4627.48 " " " " " "

4627.50 -- FIBROID TUMOR OF THE UTERUS.

2140
123
3.

A longitudinal section of the uterus has been made, and shows the tumor attached to the organ throughout its entire length. The uterus is 7 cm. long; the largest diameter of the tumor is 8 cm. It is globular, firm, and evidently a fibroma.

Presented by Dr. Mutter.

2141
123
3

4627.51 Fibroid tumor of the uterus. Presented by Dr Price

2142
123
3.

4627.52 " " " " " " " " Baldy

2143
123
4

4627.53 " " " " " " " " "

4627.54 " " " " " " " " "

2144
123
4.

4627.55 -- FIBROID TUMOR OF THE UTERUS.

2164
123
6

The tumor embraces a portion of the uterus itself, and weighed, when removed, seventeen pounds.

From Miss S.A.K., aet 27. The tumor was noticed four years previous to its removal by Dr. W. F. Atlee, July 31st, 1886. A very large incision was necessary, and its closure required eleven stitches. The tumor grew from the left cornu of the womb. The clamp was used, but removed August 5th, when the first dressing was made, and seven stitches removed. August 25th, the patient was walking about, perfectly well.

Presented by Dr. W.F. Atlee

4627 59.5 Fibroma of the Uterus.
2262
126
6

4627 57.5 Uterus :- Fibroma.
2160
123
5

4627 60.5 Uterus :- Fibroma (Missing)
2148.
123
4.

~~4627 61 Uterus :- Fibroma~~
~~2149. Pres. by Dr. Baldy.~~
~~123.~~
~~4.~~

~~4627 62 Uterus :- Fibroma~~
~~2151~~
~~123~~
~~4.~~
~~Pres. by Dr. Baldy.~~

~~4627 63 Uterus :- Fibroma~~
~~2153~~
~~123~~
~~5~~
~~Pres. by Dr. Baldy.~~

~~4627 65 Uterus :- Fibroma.~~
~~2156~~
~~123~~
~~5.~~

~~4627 67 Uterus :- Fibroma.~~
~~2158~~
~~123~~
~~5.~~
~~Pres. by Dr. C. P. Noble.~~

~~4627 67 Uterus :- Fibroma~~
~~2159~~
~~123~~
~~5~~
~~Pres. by Dr. Noble~~

~~4627 60 Fibroid, Foetus in Utero, and Placenta~~
~~2163.~~
~~123~~
~~6~~
~~Pres. by Dr. Jos. Price~~

~~4627 61 Uterus, fibroid tumor, and placenta~~
~~2165~~
~~123~~
~~6~~

~~4627 68 Myomectomy of the Pres. by Dr. Noble~~
~~2166 ... 124 ... 1.~~

~~4627 68 Uterus :- Fibroma~~
2167 ... 124 ... 1



4627.56 Fibroma of the Uterus.
2161
123
6
Removed March 3, 1853 by Dr W. F. Atlee.
See Amer. Jour. Med. Sci. Apr. 1855 p. 391.
Presented by Dr. W. L. Atlee.

2146 123 4 4627.57 Fibroma of the Uterus. Dr Drysdale

2145 123 4627.58 Fibroma of the Uterus. 2145 123 4.

2147 123 4 4627.59 Fibroma of the Uterus.

4627.60a Fibroma of the Uterus. Multiple. Presented by Dr. Slocum 2162 123 6

2150 123 4 4627.61 Fibroma of the Uterus. Presented by Dr. Drysdale.

4627.62 Fibroma of the Uterus. Presented by Dr. Noble 2152 123 5

2154 123 5 4627.63 Fibroma of the Uterus. Presented by Dr. Noble

4627.64 Fibroma of the Uterus. Presented by Dr. Noble 2155 123 5

2157 123 5 4627.65 Fibroma of the Uterus. Presented by Dr.

2170 4627.66 Fibroma of the Uterus. See Vol. II Pg. 155 Dr. W. L. Atlee

2159 4627.67 Fibroma of the Uterus. Presented by Dr Noble. See Vol II Pg. 155

4627.68 " " " " Presented by Dr. Noble *

4627.69 " " " " Submucous and interstitial
2168
124
1.
Hysterectomy for hemorrhage -
Presented by Dr G. E. Shoemaker

4627.70 Fibroma of the Uterus. Hysterectomy.
2171
124
1.
Case of Mrs. Van Horn. Presented by Dr. Shoemaker.

4627.71 Fibroma of the Uterus. Removed with ovaries.
2169
124
1.

~~4627 66 Fibroma of the Uterus.~~
~~2170~~
~~124~~
~~1.~~

* One specimen (myomectomy) also numbered 4627.68 Destroyed by auth. Mutter Committee Jan. 6 - 1941
Number was duplicated in error.
Dr. J. Parsons Schaeffer
Dr. Harry O. Schenck
Dr. Baldwin Luché
} Committee

4627.605 -- FIBROID TUMOR OF THE UTERUS. PLACENTA PREVIA IN SITU. Foetus in utero. *Presented by* Dr. Price 1891

~~4627.605~~ ~~*Fibroma of the Uterus.* Presented by Dr. Joseph Price, 1891.~~

4627.606 *Fibroma of the Uterus. Presented by Dr. Noble.*

4627.61 -- FIBROID TUMOR OF THE UTERUS; OBLITERATION OF THE UTERINE CAVITY, AND OBSTRUCTION OF THE CERVICAL CANAL.

The mass on removal was somewhat triangular in shape, with rounded angles. Its circumference transversely around the upper and widest part was 5 cm. The circumference measured around its vertical diameter was 38 cm. The color was glistening and of a fibrous appearance; on palpation it gave the sensation of a tensely filled sac. No openings for the Fallopian tubes were visible to ordinary ocular inspection. A small piece of the vagina, and about one-fourth of the os uteri were comprised in the specimen. No cervical or uterine cavity could be found, the entire lumen being occupied by a mass which presented an irregularly rounded portion, entirely filling the distended os.

On section the tumor was found to be solid throughout, and to consist of a mass which sprang from almost the entire extent of the inner layer

of muscular tissue of the uterine wall, and, growing concentrically, had produced entire obliteration of the cavity, and, at the same time, great and symmetrical enlargement of the uterine mass. The tumor in places strikingly resembled muscular tissue. Microscopic examination showed it to be a myoma, consisting of elements homologous with the tissue of the uterus, namely,- Spindle-shaped cells, imperfectly developed muscular fibre cells, and some curly elastic fibres. The mass was invested by the thickened peritoneal capsule, and by the external layer of muscular tissue of the uterine walls; it could readily be stripped away from these. Weight, 1.8 kilogrammes (5 lbs).

Removed successfully from a woman aet. 52 yrs. Menstruation suddenly ceased on learning of the death of her son on the battle-field. Pain occurred in the right side of the pelvis, and a tumor made its appearance and increased in size. It was situated to the right of the linea alba, and to the touch felt like a cyst, with thick and tightly stretched walls. The neck of the womb was normal in size and position. The uterine probe could not be introduced quite as far as usual into the cavity of the womb. The tumor was felt to be quite firmly attached at its lower part; when the hand was placed over it, and attemps were made to move it from side to side, these movements were

not felt to be communicated to the uterine neck. Diagnosis: Cystic tumor of the right ovary. Abdominal section was performed, and, after removing the adhesions, the whole mass was removed, the clamp being applied around the upper part of the vaginal canal.

Perfect recovery followed.

Presented by the operator,

Dr. Walter F. Atlee.

Trans.Coll.Phys.Phila., Vol.IV, p. 387. April 1871

2149 123 4 4627.615 *Fibroma of the Uterus.* *Presented by Dr. Baldy.*

2151 123 4

2153 123 5 4627.625 *Presented by Dr. Baldy.* *Fibroma of the Uterus.*

4627.635 *Fibroma of the Uterus.* *Presented by Dr. Baldy.*

4627.655 FIBROMA OF THE UTERUS.

2156 123. 5

The specimen is a very large one, weighing about 30 lbs. It was removed post mortem from Miss M. Menorrhagia and hemorrhage had been absent. Patient said the tumor seemed softer during menstruation. Diagnosis: Fibroid or Colloid tumor.

Abdominal section was performed by Dr. Washington L. Atlee. Adhesions and great vascularity added to the dangers of the operation. The plan of extirpation was abandoned, and efforts were made to control hemorrhage. Death occurred on the fifth day from exhaustion.

Post Mortem. The tumor was found firmly adherenet in every direction; it was found to have taken its origin from the anterior surface of the uterus about midway between the os tincae and fun-

4627.69 Intraligamentous Fibroid and Tubo-
2173
124 Ovarian abscess.
2.

Pres. by Dr. G. E. Shoemaker.

4627.72 Tumor of the Uterus.
2174
124
2.

4627.73 Tumor of the Uterus.
2175
124
2.

4627.74 Fibro cystic tumor of the uterus. Weight, ninety seven pounds
Presented by Dr. T. M. Drysdale.
~~4627.75 Soft Myoma of uterus.~~

4629.02 Ovarian Cyst.
2179
124 Pres. by Dr. Joseph Price.
6.

2 specimens with this number one in case 94-shelf-2-
other destroyed 11-?-40

4628 Fibroid Tumor of the Uterus.
2834 Pres. by Dr. J. M. Baldy
124 3.5.02.
2.

4628.1 Intraligamentous Fibroma (Uterus)
2840
121 Hysterectomy.
4. Pres. by Dr. Geo. E. Shoemaker

4627.75 Uterine Polypus.
2841 Removed by Ecraseur. 11.21.02.
124 Pres. by Dr. Cleeman.
2.





dus, attached by a short pedicle one inch in breadth and a quarter of an inch in thickness. The uterus was retroverted, and the neck much elongated. Just above the point of attachment of the pedicle and to the left there was a hard tumor about the size of a filbert. The surface of the large tumor is smooth and regular in outline, except on the right side just above its inferior border; at this point there is a marked projection. The tumor was soft, elastic, very vascular and discolored. Both gross and microscopical examination confirmed the opinion of its fibroid character.

Presented by Dr. J. E. Mears.

Trans. Phila. Path. Soc'y, Vol. III, p. 87. See Vol II Pg. 141

2170 124 1 4627.66 Fibroma of the Uterus. Presented by Dr. W. L. Atlee. 2159 123 5
4627.67 Fibroma of the Uterus. Presented by Dr. C. P. Noble
~~4627.68 Fibroma of the Uterus. Presented by Dr. John B. Roberts.~~ Vol II Pg 141

4629. -- UTERUS; "OSSEOUS TUMOR."
2181.
124.
1.

The uterus is about 9 cm. long, is nodulated, and on section shows a growth of a calcareous nature.

Presented by Dr. Corse.

Dr. Joseph Price

2176
124
5.

4624.15 see Vol II Page 129
~~4620~~ Malignant adenoma of the Uterus.
2182.
124 From a patient 70 years of age. Presented by Dr Shoemaker
1

4624.20 see Vol II Page 129
~~4620~~ Adenoma of Uterus Presented by Dr. M. B. Werner.

2183
124
1

Destroyed May, 1942 - Auth. Dr. McFarland, Curator Mutter Committee - Dr. J. P. Schaffer Dr. R. P. Custer Dr. O. V. Batson

4629-3 Uterus and appandages. Fibrous tumor of the uterine wall enclosed in a calcareous shell. Ovarian cysts.

The uterus is enlarged and thickened at the neck. In the anterior wall, there is an interstitial tumor about as large as a small lemon, having a bone-like shell with dense fibrous contents; near it was another small fibrous tumor. There was a polypus at the uterine orifice of the left Fallopian tube and another crest-like in shape at the side of the cavity near the neck. The ovaries were hypertrophied and cystic.

From Mrs. M., aet. 55, the mother of three children. Abdominal swelling had existed for seventeen years and she was repeatedly aspirated. Death ensued from exhaustion.

Trans. Phila. Path. Society, Vol. II, p. 137.

Presented by Dr. John H. Packard,

4629.4 Fibroma of the uterus Calcareous Degeneration
2176
124
5
Dr. Joseph Price

4624.15 see Vol II page 129
~~4620~~ Malignant adenoma of the Uterus.
2182.
124
1
From a patient 70 years of age. Presented by Dr Shoemaker

4624.20 see Vol II page 129
~~4620~~ Adenoma of Uterus Presented by Dr. M. B. Werner.
2183
124
1

462
284.
124
2.
Pres. by Dr. Cleeman.

4632. Round cell Sarcoma of the Uterus
2184
124
3. 11.22.95. Presented by Dr J.M. Baldy.

4633. Missing Cancer of the Uterus.-
2180 In one case a hysterectomy has been
124 done in the other a vaginal- Hysterectomy
6 Pres. by Dr. H. A. Kelly.

4634. -- CANCER OF THE UTERUS.
2185
124
3.

Only a portion of the growth has been preserved. It is shaggy, contains fibrous tissue in abundance, arranged to form small alveoli, and hanging from its substance are many small, pedunculated cancerous bodies. Presented by Dr. Corse.

4634.12 Cancer Fundus Uteri. 11.101
2842. Pres. by Dr. J. M. Baldy. Remounted 1.12.02
124
3



4634.45 Cancer of the uterus and ovaries.
Presented by Dr. Drysdale.



4634.01 Malignant adenoma of the Cervix
2186
124
3.
Hysterectomy. Presented by Dr. G.E. Shoemaker. (42)

~~ulated cancerous bodies.~~

Missing
4634.101 Cancer of Uterus & ovaries " " "
4634.2 Adeno Carcinoma of the Uterus. Hysterectomy.
2187.
124
3. Presented by Dr. G.E. Shoemaker.

4634.10 -- CANCER OF THE UTERUS.

2188
124
3.

The tumor is spherical, and has a diameter of 9 cm. It is of smooth, regular outline, is dense, abounds in fibrous tissue, and is probably an epithelial cancer.

Removed Post Mortem from a woman, aet. 62 years. It was taken from the cavity of the Uterus, and was partly encysted in its walls.

Presented by Dr. W. L. Atlee.

4634.11 Epithelioma of the Cervix uteri. Vaginal Hysterectomy. 4.4.96.
2189
124
3. Case of Mrs. Hunter. Therap. Gazette Oct. 96 Presented by Dr. G. E. Shoemaker.

4634.25 -- UTERUS AND APPENDAGES. CANCER.
2190
124
3.

The disease involved the fundus of the uterus and surrounding tissues.

Presented by Dr. J. M. Corse.

~~4634.21 Epithelioma of the Cervix. Vaginal Hysterectomy~~
~~Case of Mrs. Hunter. Therap. Gazette. Oct. 1896.~~
~~Presented by Dr. G.E. Shoemaker~~

4634.30 -- EPITHELIOMA OF THE CERVIX UTERI.
2191
124
3.

Vaginal nysterectomy by Dr. Jno. B. Roberts.

Recovery.

Presented by Dr. Roberts.

Missing
4634.35 Epithelioma of the Cervix.
2192
124
3 Hysterectomy Presented by Dr Hirst.
2193 Missing
124 4634.40 Epithelioma of the Cervix. Presented by Dr. Hirst.
3

4654.1 -- UTERUS AND APPENDAGES. Pg. 163 Vol E

Dropsy of the right Fallopian tube.

4659. Pyosalpinx. Hysterectomy.
2237
126
1. Pres by Dr. C. P. Noble.





4656. -- HYDROSALPINX.
2201
125
1.

Two ovaries and tubes; large hydrosalpinx; left tube larger.

In the same jar are two ovaries and tubes from fibro cystic uterus; right ovary larger.

Presented by Dr. H. A. Kelly.

2203
125
1. 4656.10 Double Hydrosalpinx. Presented by Dr Baldy.
2204
125
1. 4656.20 " Hydrosalpinx. Presented by Dr. Price.
2205
125
1. 4656.30 "
4658. -- UTERUS AND FALLIOPIAN TUBES; THE LATTER DISTENDED.
2234
126
1.

The tubes are greatly distended, appearing almost of the size of the kidney. The contents were cheesy, probably degenerated menstrual fluid.

From the Philada. Hos pital.

4659.1 -- PYOSALPINX; ENORMOUS SIZE.
2235
126
1

From a woman aet. 25. Laparotomy death on third day. At the autopsy cystitis, inflammation of ureter and abscess of right kidney were found.

Presented by Dr. J. M. Baldy.

4659.05 Pyosalpinx
2206
125
1.
2236
126
1 4659.06 Pyosalpinx. a series of specimens Removed by D Joseph Price. D B.C. Hirst.
4659.08 -- PYOSALPINX; WITH CYST OF BROAD LIGAMENT.
Pg- 163- Vol. II
2207
125
2.

Removed by Dr. Joseph Price, Jan. 26th, 1887.

2208
125
2 4659.11 Pyosalpinx. Presented by D- J.M. Baldy.
2209
125
2 4659.12 " " " " "
2210
125
2 4659.13 " " " " "
4659.14 " " " " "
2211
125
2.

4659 1455 Oophoritis.
2245
126
3

4659 1441 Pyosalpynx and diseased Ovary.
2244
126
3.
Pres. by Dr. C. B. Penrose.

4659.1415 Pyosalpinx Presented by Dr Penrose.
2219
126
3
Case of Mrs. Nothnagel. 9/6/93.

4659.142 missing Double Pyosalpinx, (Tubercular)
Hysterectomy 10.10.95. K.H.
Presented by Dr. C. P. Noble.

2212 4659.143 Oophoritis
125
2

2213 4659.144 Oophoritis
125
2

4659.144 Oophoritis
Presented by Dr. Penrose.
Case of Mrs Oldshaw.

2238 4659.1457 Oophoritis
126
2

2239 4659.146 Oophoritis.
126
2

2240 4659.147 "
126
2

2241 4659.148 "
126
2

2242 4659.149 "
126
2

4659.1491 Pyosalpinx. Right tube and ovary.
2243
126
2.
Case of Mrs. Anna Hurley - Opn Oct. 3. 1896.
Presented by Dr. Shoemaker.

4659.1495 Oophoritis
2214
125
3
Pres. by Dr. Penrose.



4661. Tumor of the Fallopian Tube.
2248 Pres. through Prof. Parvin 11/15/87 by Dr. Redpath
126
3. Fort Steilacoom, Washington Territory.

~~4664.2~~
~~2247~~
~~126~~
~~3.~~

4664.2. Fibroma of the Right Broad Ligament
2221 without attachment to neighboring tissues.
125
4. Presented by Dr John C. Da Costa.

4666.1 Cyst of Broad Ligament.
2223
125
4.

4666. Cyst of the Broad Ligament.
2230 Pres. by Dr. Drysdale.
125
6



Missing

4659.15 -- PYOSALPINX; OÖPHORITIS.

Annotated

The tube emptied into the ovary, which held three ounces of pus. Gonorrheal history.

Removed May 5th, 1886, by Dr. Howard A. Kelly.

2215 125 3
4659.16 Pyosalpinx. Presented by Dr. John B. Roberts.
2216 125 3
4659.17 Pyosalpinx; discharging into the bowel.
4659.18 Pyosalpinx. Presented by Dr. Baldy
2217 125 3
2218 125 3
4659.19 " " " " noble

4661. -- TUMOR OF THE FALLOPIAN TUBE; ~~FIBRO-CALCAREOUS~~.

The tumor was in the fallopian tube attached to the uterus and was 1 1/2 inches from the ovary which was not involved and apparently healthy. Removed Post Mortem from Mrs. L.E. aet 42 years insane for two years. XI para. Youngest aet 6 yrs. Believed herself pregnant.

From Dr. N. J. Redpath,

Fort Steilacoom, Wash. Terr.

Through Dr. J. Parvin.

4660 Diffuse Tuberculosis of the uterine appendages
2246 Presented by Dr. Baldy.
126
3

(2247) old no.

4664. -- TUMOR OF THE FALLOPIAN TUBE AND BROAD LIGAMENT.

4664.1 destroyed 11-?-46 by order of Mutter Committee

4664.1 TUMOR of the Ovary and Fallopian tube
2220 Presented by Dr J. H. Packard.
125
4. See Trans. Phila Obstet. Socy. 2.17.87.

2222 125 4.
4666 Cyst of the Broad Ligament. Presented by Dr Drysdale

4680. -- CICATRIX AFTER OVARIOTOMY.

2224
125
4.

Sixteen years after the operation on post mortem examination, the cicatrix was found scarcely traceable, being a small line in the linea alba, 8 cm. long. The abdominal walls were thin, containing little adipose tissue. The pedicle is attached to the under surface. No adhesions or traces of inflammatory action could be found at any point. Visceral and parietal surfaces of peritoneum, smooth and glistening; Uterus small; position normal; freely movable the length of the pedicle. Right ovary healthy, firm and contracted.

4661. Tumor of the Fallopian Tube.
2248
126
3.
Pres. through Prof. Parvin 11/5/87 By Dr. Redpath
Fort Steilacoom, Washington Territory.

~~4662~~ 2
~~2247~~
~~126~~
~~3.~~

4664.2 Fibroma of the Right Broad Ligament
2221
125
4 Without attachment to neighboring tissues.
Presented by Dr John C. Da Costa.

4666.1 Cyst of Broad Ligament.
2223
125
4.

4666. Cyst of the Broad Ligament.
Pres by Dr. Krysdale.
2230
125
6





Missing

4659.15 -- PYOSALPINX; OÖPHORITIS.

Unidentified

The tube emptied into the ovary, which held three ounces of pus. Gonorrheal history.

Removed May 5th, 1886, by Dr. Howard A. Kelly.

2215
125
2

4659.16 Pyosalpinx. Presented by Dr. John B. Roberts.
4659.17 Pyosalpinx; discharging into the Bowel.
4659.18 Pyosalpinx. Presented by Dr. Baldy. 2217 125 3
4659.19 " " " " "
4661. -- TUMOR OF THE FALLOPIAN TUBE; ~~FIBRO CALCAREOUS.~~

The tumor was in the Fallopian tube attached to the uterus and was 1½ inches from the ovary which was not involved and apparently healthy. Removed Post Mortem from Mrs. L.E. aet 42 years insane for two years. XI para. Youngest aet 6 yrs. Believed herself pregnant.
From Dr. N. J. Redpath,

Fort Steilacoom, Wash. Terr.

Through Dr. J. Parvin.

4660 Diffuse Tuberculosis of the Uterine appendages
2246 Presented by Dr. Baldy.
126
3

(2247) deaths

4664.1 destroyed 11-7-46 by order of Committee
4664. -- TUMOR OF THE FALLOPIAN TUBE AND BROAD LIGAMENT.
4664.1 TUMOR of the Ovary and Fallopian Tube
2220 Presented by Dr. J.H. Packard.
125 See Trans. Phila Obstet. Socy. 2.17.87.
4
2222 125 4 4666 Cyst of the Broad Ligament. Presented by Dr Krysdale
4680. -- CICATRIX AFTER OVARIOTOMY.

2224
125
4.

Sixteen years after the operation on post mortem examination, the cicatrix was found scarcely traceable, being a small line in the linea alba, 8 cm. long. The abdominal walls were thin, containing little adipose tissue. The pedicle is attached to the under surface. No adhesions or traces of inflammatory action could be found at any point. Visceral and parietal surfaces of peritoneum, smooth and glistening; Uterus small; position normal; freely movable the length of the pedicle. Right ovary healthy, firm and contracted.

4661. Tumor of the Fallopian Tube.
2248 126 3. Pres. through Prof. Parvin 11/15/87 by Dr. Redpath
Fort Steilacoom, Washington Territory.

~~4664.2~~
~~2247~~
~~126~~
~~3.~~

4664.2 Fibroma of the Right Broad Ligament
2221 125 4. without attachment to neighboring tissues.
Presented by Dr John C. Da Costa.

4666.1 Cyst of Broad Ligament.
2223 125 4.

4666. Cyst of the Broad Ligament.
2230 125 6 Pres. by Dr. Drysdale.



Missing

4659.15 -- PYOSALPINX; OÖPHORITIS.

Annotated

The tube emptied into the ovary, which held three ounces of pus. Gonorrheal history.

Removed May 5th, 1886, by Dr. Howard A. Kelly.

2215 125 2
4659.16 Pyosalpinx. Presented by Dr. John B. Roberts.
2216 125 3
4659.17 Pyosalpinx; discharging into the bowel.
4659.18 Pyosalpinx. Presented by Dr. Baldy
2218 125 3
4659.19 " " " " noble
2217 125 3

4661. -- TUMOR OF THE FALLOPIAN TUBE; ~~FIBRO-CALCAREOUS~~.

The tumor was in the fallopian tube attached to the uterus and was 1 1/2 inches from the ovary which was not involved and apparently healthy. Removed Post Mortem from Mrs. L.E. aet 42 years insane for two years. XI para. Youngest aet 6 yrs. Believed herself pregnant.

From Dr. N. J. Redpath,

Fort Steilacoom, Wash. Terr.

Through Dr. J. Parvin.

4660 Diffuse Tuberculosis of the uterine appendages
2246 126 3 (2247) old no. Presented by Dr. Baldy.

4664. -- TUMOR OF THE FALLOPIAN TUBE AND BROAD LIGAMENT.

4664.1 destroyed 11-?-46 by order of Mutter Committee
4664.1 TUMOR of the Ovary and Fallopian tube
2220 125 4. Presented by Dr J. H. Packard.
See Trans. Phila Obstet. Socy. 2.17.87.
2222 125 4.
4666 Cyst of the Broad Ligament. Presented by Dr Drysdale

4680. -- CICATRIX AFTER OVARIOTOMY.
2224 125 4.

Sixteen years after the operation on post mortem examination, the cicatrix was found scarcely traceable, being a small line in the linea alba, 8 cm. long. The abdominal walls were thin, containing little adipose tissue. The pedicle is attached to the under surface. No adhesions or traces of inflammatory action could be found at any point. Visceral and parietal surfaces of peritoneum, smooth and glistening; Uterus small; position normal; freely movable the length of the pedicle. Right ovary healthy, firm and contracted.

Uterine arteries calcareous; bladder in a state of chronic inflammation, with thickened walls.

From a woman who, after great physical and mental distress, submitted to ovariotomy by Dr. W. L. Atlee, January 3rd, 1852. She was at that time 67 years old, had married when twenty-three years old, and had seven children. Labors were severe, but not instrumental; no miscarriages.

See Trans.Path.Soc'y, Phila., Vol.III, P.~~71~~ 69, 1868; also Amer.Jour.Med.Sciences, Vol.56, p.~~157~~ 153. - 157 - 1868

Presented by Dr. J. E. Mears.

4680.10 -- CICATRIX SIX YEARS AFTER OVARIOTOMY.

2249
126
3

On examination post mortem, the cicatrix was dark; the adipose tissue of the belly walls became exceedingly thin at the cicatrix. No peritonitis or adhesions. The pedicle is adherent to the cicatrix, and on each side of it the peritoneum was continued to the brim of the pelvis. By means of these two broad attachments a large number of vessels found their way to the uterus and the remaining right ovary. The right ovary, Fallopian tube, etc., were healthy, save that a cyst the size of a pea existed at one point. The ovary also showed a very marked and recent corpus luteum, probably but a few days old. The uterus was very much tilted upwards to the left side by the traction of the pedicle. Its neck was greatly elongated. The os uteri was not fissured, and the rugae of the

vagina were still distinct.

From the body of M.G., who, when sixteen years of age underwent ovariotomy by Dr. W. L. Atlee, after six tappings. The left ovary, consisting of one large cyst with a polycystic mass in its anterior wall was removed. Weight 32 lbs.

The girl became a prostitute, was once pregnant miscarried, and died of typhus fever.

See Amer.Jour.Med.Sciences, Vol.55, p.407. 1868

Presented by Dr. W. W. Keen.

4725.01 -- UTERUS AND APPENDAGES. COMMENCING CYSTIC DISEASE.

2250
126
4.

Presented by Dr. W. L. Atlee.

4725.02 -- UTERUS AND APPENDAGES. SMALL OVARIAN CYSTS.

2251
126
4.

Presented by Dr. W. L. Atlee.

4725.03. -- UTERUS AND OVARIES; CYSTIC DISEASE.

2252
126
4.

The uterus is greatly enlarged and both ovaries are cystic.

Presented by Dr. Corse.

4725.031
2253
126

Uterus and appendages. Cystic and fibroid
4. Ovaries.

Presented by Dr. Baldy.

4725.04 -- CONTENTS OF AN OVARIAN CYST. (Two specimens.)

Mr. Atlee=2254 } Sect. Shelf
Mr. Drysdale=2255 } 126. 4

The specimen consists of myriads of small spherical bodies, resembling the roe of shad, measuring about 1 millimeter in diameter. They consist chiefly of fat.

Presented by Drs. W. L. Atlee & T. R. Drysdale.

missing

4725.05 -- UNILOCULAR OVARIAN CYST; DISTENDED AND DRIED.

2225
125
5

Greatest circumference, 52 cm.

Presented by Dr. W. L. Atlee. (Missing)

missing

4725.06 -- UNILOCULAR CYST OF RIGHT OVARY; DISTENDED

2226
125
5

AND DRIED.

From Mrs. McM. (Missing)

missing

4725.07 -- UNILOCULAR OVARIAN CYST; DISTENDED AND DRIED.

2227
125
5

Long diameter, 25 cm.

Presented by Dr. W. L. Atlee. (Missing)

missing

4725.08 -- UNILOCULAR OVARIAN CYST; DISTENDED AND DRIED.

2228
125
5

Long diameter, 29 cm.

Presented by Dr. W. L. Atlee. (Missing)

missing

4725.09 -- OVARIAN CYST WITH DIVERTICULI; DISTENDED AND DRIED.

2266
127
2.

Long diameter, 27.5 cm. (Graham).

(Missing)

missing

4725.10 -- OVARIAN CYST; DISTENDED AND DRIED.

2283.
128
1.

Long diameter, 29.5 cm. (Mrs. Repler).

Presented by Dr. W. L. Atlee.

(Missing)

4725.11 -- OVARIAN CYST; DISTENDED AND DRIED.

2264
127
1

Long diameter, 26.5 cm. The cyst is large, and has several diverticuli.

Presented by Dr. W. L. Atlee.

(Missing)

4725.12 -- BILOCULAR OVARIAN CYST; DISTENDED AND DRIED.

2284
128
1.

There are two cysts, having diameters of 20 and 33 cm. respectively. The pedicle seems to have been 5 cm. broad.

Section 98

Presented by Dr. W. L. Atlee.

4725.13 -- UNILOCULAR OVARIAN CYST; DISTENDED AND DRIED.

2265
127
1.

The cyst is globular as dried, and has a diameter of 31 cm.

From Mrs. E. T., aet. 46; widow; never con-

4725 149 Ovarian Cyst. Distended and dried
2268
126
5
(Missing)

4725 1495 Ovarian Cyst. Distended and dried.
2308
129
1.
(Missing)

4725. 151 Ovarian Cyst. (Missing)
2354
131
1.

4725 152 Ovarian Cyst. (Missing)
2355.
131
1.



(49)

ceived. Left ovary containing about 40 lbs. of clouded, transparent, pale fluid; a pelvic abscess was also emptied at the time of the operation by puncturing through the roof of the vagina, one pint of pus escaping.

(Dr. Atlee's 177th operation.)

Sec. 98

Presented by Dr. W. L. Atlee.

4725.14 -- OVARIAN CYST; DISTENDED AND DRIED.
2307.
129.
1.

The cyst has numerous diverticuli; the long diameter is 43 cm.

Sec. 98

Presented by Dr. W. L. Atlee.

4725.15 -- OVARIAN CYST; DISTENDED AND DRIED.
2330.
130.
1.

The cyst is of globular shape with a diverticulum. Long diameter, 40 cm.

From Mrs. John Waite, May 25th, 1864.

Sec. 98

Presented by Dr. W. L. Atlee.

4725.16 -- LARGE OVARIAN CYST; DISTENDED AND DRIED.
2328
130
1.

From Miss S. Makins; operation May 18, 1865.

Weight of tumor tissue 4 lbs.; contents 70 lbs.

Presented by Dr. W. L. Atlee. Sec. 98

4725. 165 Ovarian Cyst. Distended and dried.
2229
129
5
Presented by Dr J.E. Means. (Missing)

4725. 166 Ovarian Cyst. Distended and dried
2257
4. 126
5
Presented by Dr Hirst
(Missing)

~~4725.166~~
~~2846~~
~~126~~
~~4.~~

4725.167
2258
126
5
Multilocular ovarian cyst. Removed from a patient aged 76.
Presented by Dr A.B. Hirsh.
(Missing)

4725.168 Ovarian cyst.
2285
128
1
Removed from Miss Mixson, Media, Pa. The fluid contents filled a washtub and three buckets.
Dec. 98
Presented by Dr L. Brinkmann.

2267
127
2
4725.169 Ovarian cyst multiple Pres. by Dr. Drysdale.

4725.170 Fibro cystic tumor of the ovary
2231
125
Presented by Dr Drysdale (Biology)
Feb. 1938

2232
125
6
4725.171 " " " " (Missing)

2256
126
4
4725.172 " " " Noble (10)

4725.173
2286
128
Case of Mrs Parsons. K.H.

2309
129
2.
4725.174 " " Nancy ayres Presented by Dr. Drysdale

(Missing)
4725.175 Ovarian cyst multilocular
2263
126
6.
Case of Mrs. Walker. Autopsy 5.30.'88.
Presented by Dr. Drysdale.

Dr storeroom case 1-
Bottomley

(50)

Destroyed

4725.17 -- CONCENTRIC CYSTOMA OF THE BROAD LIGAMENT,
2259.
126.
5.
OVARY AND FALLOPIAN TUBE.

Removed from a woman aet. 29 yrs., Oct. 7th,

p. 191A

Philad$^{a}$ Oct. 5$^{th}$ 1869.

1869 Oct. 5

Freind G. H. Horn

Sir in answer
to your queries I transmit the
following

John Benton Campbell
Born May 30$^{th}$ 1842
First complained of pain in the
arm in the Summer of 1866
Physician prescribed for Reumatism
arm commenced Swelling in the
fall, Was first taken to bed
Dec 25$^{th}$ 1866
The increase of arm was about one
inch each week
A few day before death its measured
28 inches in circumference
He complained of pain in the
breast and back, which his
parents thought was caused
by displacement of the shoulder
blade is being pressed out of place

Mütter Museum.

Presented by Dr. J. C. Da Costa.

(50)

Destroyed

4725.17 -- CONCENTRIC CYSTOMA OF THE BROAD LIGAMENT,
2259.
126.
5.
OVARY AND FALLOPIAN TUBE.

Removed from a woman aet. 29 yrs., Oct. 7th,

At one time there was 15 ulcers which discharge a watery matter, the ulcers united forming 9, discharging a darker fluid accompanied by lumps resembling flesh; about the size of a hickory nut
There was no haemorrhage until a few moments before death which occured July 12th 1857 Aged 5 1/3 years
He bleeding to death in a few seconds

Your's
Jas. H. B. Bland

Presented by Dr. J. C. Da Costa.

From
Jas. H B Bland
Oct 5. 1869
About a case.

?



Destroyed

4725.17 -- CONCENTRIC CYSTOMA OF THE BROAD LIGAMENT,
2259. OVARY AND FALLOPIAN TUBE.
126.
5.

Removed from a woman aet. 29 yrs., Oct. 7th, 1866. Weight, with contents, 16 lbs.

There are two concentric cysts. The exterior one was peritoneal, embracing the Fallopian tube; "the interior one, the tumor proper."

The cyst has been distended and dried; the long diameter is 30 cm.

Presented by Dr. W. L. Atlee.

Destroyed February 1938 by action of the Committee of the Mütter Museum because it was badly deteriorated and therefore of no value -

(5) 4725.18 -- MULTILOCULAR CYST OF LEFT OVARY.
2268
127.
2.

Weight, 25 lbs. Removed April 20th, 1887.

Also

Hernial Sac (Femoral); left side removed from same patient April 24, 1887 (four days later).

Patient well in three weeks from first operation, and discharged well a week later. (May 18, 1887).

Patient when operated on had weak lungs, weak heart (with intermittant pulse), Chronic Albuminuria, Degenerated condition of blood vessels, Double Hernia, Ovarian tumor, and previous history of Acute Dementia.

Mütter Museum.

Presented by Dr. J. C. Da Costa.

4725.[181] ~~4825.[181]~~ Two ovarian cysts growing from the left ovary. Presented by Dr Noble.

4725.[182] ~~4825.182~~ Ovarian Cyst " " Dr Drysdale Missing

4725.[183] ~~4825.183~~ " " Missing

4725.[184] ~~4825.184~~ " " Missing

4725 213 Ovarian Cyst.
2312
129
2.
Pres. by Dr. Drysdale

4725 26 Ovarian Cyst.
2233
125
6.
Pres. by Mrs. { Mr. T. Willard / S. W. Wilson

4725 231 Cystic and Fibroid Ovaries &
2351
130
5.
Pres. by Dr. Mears. Missing

4725 235 Ovarian Cystoma.
2467
134
6.

4725.261 (2292) Ovarian Cyst — Presented by Dr. Drysdale
4725.27 (2315) Ovarian Cyst — Presented by Dr. Drysdale.
4725.28 (2316) Ovarian Cyst — Presented by Dr. Drysdale
4725.29 Ovarian Cyst.





(51)

2305 128 5 — 4725.185 Multilocular Ovarian Cyst.
2269 127 2. — 4725.186 " " " Dr B.C. Hirst.

4725.19 -- UNILOCULAR OVARIAN CYST.
2289
128
2.
Presented by Dr. J. Ewing Mears, 2-28-87.

4725.191 2310 129 2. Unilocular ovarian Cyst Presented by Dr Hirst
4725.192 Ovarian cyst. " " Dr Drysdale — Missing

4725.20 -- OVARIAN CYST WHICH, WITH CONTENTS, WEIGHED
2378.
131.
5.
100 LBS. Missing

Removed and presented by Dr. H. A. Kelly.

4725.201 Ovarian cyst Missing
2096 121 3 — 4725.202 " " Presented by Dr Drysdale
2097 121 3 — 4725.203 " " " " " — Missing

4725.21 -- CYSTIC OVARY AND DISEASED TUBES.
2293.
128
8. to reason.
Removed for Ovarian insanity - Recovery and restoration
Presented by Dr. C. M. Wilson.

2315 129 2 — 4725.211 Cystic Ovaries.
4725.212 " " " " J. M Drysdale
2261 126 6 — 4725.214
4725.22 -- CYSTIC OVARIES DISEASED TUBES. Spoiled.

Presented by Dr. C. W. Dulles

2290 128 2 — 4725.23 Cystic and fibroid ovary - Presented by Dr. Baldy.
4725.24 Cystic Ovary. " " " Mears. — Missing
2291 128 2 — 4725.25 Cystic and fibroid ovary.

4730. -- DERMOID CYST OF THE OVARY; WITH FIBROIDS.
2314
129
2.
Fallopian tube, eleven inches long.

Presented by Dr. G. E. Shoemaker.

4730.05
2339.
130
3.
Dermoid Cyst, showing Superior Maxilla with Teeth, Hair, Skin, and the Head of the Femur. Presented by Dr. J. M. Baldy.

4736. -- DISEASED UTERUS AND OVARIES.
2343
130
3.
Presented

4730.10
2340
130
3.
Dermoid Cyst of the Ovary.

4730.11 missing Dermoid cyst of the left ovary from a patient four years old; containing long hair and bone

Presented by Dr W.C. Goodell.

4730.12 Dermoid cyst
2341.
130
3. Case of Mrs Forman Removed Dec. 20. 1894 at The Kensington Hospital for Women.

Presented by Dr. C.P. Noble.

4730.13 Dermoid cyst of left ovary, showing teeth, hair and bone. Weight — Removed 9 weeks after labor.
2270
127
3.

Presented by Dr J.C. Dacosta.

1898.

4730.141 Hair from Dermoid Cyst of ovary.
2329. Missing Presented by Dr John C. DaCosta.
130
1.

4730.14 Hair from Dermoid Cyst of Ovary.
2358.
131.
2. Pres. by Dr. J.C. DaCosta.

4772
2468.
13B
6.

4745.05 Pediculated Fibroma of both Ovaries
Presented by Dr. Richard A. Cleeman
see Pg. 134-Vol. II





(52)

4730.20 Dermoid Cyst. Dr. B.C. Hirst.
2342.
130.
3.

4737. -- TUBERCULOUS OVARY.
2356.
131.
1.

Presented by Dr. Baer, 5-22-88.

4746.05 Small spindle-celled Sarcoma of the Ovary Dr Baldy 2357 131 1.

4746 Sarcoma in the Wall of an Ovarian Cyst Presented by Dr. Baldy
2352
130
5

4750. -- LARGE SCIRRHUS OF THE OVARY.
2359.
131
2.

Presented by Dr. Mütter.

4770. -- TUMOR.
2360.
131.
2.

Dr. W. L. Atlee..

4770.10 -- TUMOR.
2361
131.
2.

Dr. W. L. Atlee.

4800. -- MYXOMATOUS DISEASE OF THE CHORION ( SO CALLED HYDATIDS).
2271
127
3.

The specimen consists of a solid growth of a yellowish color (the chorion), with innumerable white vesicles (the villi), varying in size from a pin head to the size of a small grape. The cysts are shrunken; when recent they were pinkish, translucent, and contained a clear limpid fluid. The cysts hang in festoons, have long pedicles springing from the chorion itself, or from other cysts.

From a married woman who supposed herself pregnant, was suddenly taken sick, and after the usual labor pains was delivered of this large mass.

Presented by Dr. Mutter.

4826 181 Two Ovarian Tumors. Left Ovary.
2296 Pres. by Dr. Noble.
128
3

Pg. 193
47 25.181
47 25.182

4825 182 Ovarian Cyst.
2297 Pres. by Dr. Brysdale.
128
3.

missing

4835. 105 Uterus and appendages

4815. Triplets - Abortion at 4 1/2 months. No cause
2292 for abortion known. Mother aged 28, had 9 foetuses in
128 6 years. 4 born at term. 2 single miscarriages & one
2. Triple miscarriage Presented by Dr A.P. Charlton.

4815. 15 Tubes ovaries and uterus from a woman
2276 suffering from puerperal septicaemia two weeks
127 after criminal abortion. Both tubes contained
4. pus and the uterus contained a suppurating
placenta which is yet in situ, Patient at the
time of operation in a dying condition -
Presented by Dr. J.M. Baldy

4815. 10 Tubes ovaries and uterus removed from
2277 a patient ten days after abortion. Broad liga-
127 ment and uterine walls contained pus; tubes
4 and ovaries healthy. Patient in an exceedingly
bad condition dying at the time of operation.
Presented by Dr. J.M. Baldy-

2294 4815. 20 abortion at 3 months - Spontaneous or
128 due to the effects of adhesions produced at second
3 delivery. For 2 months the patient had constant
pain in the abdomen and especially in the pelvis
Abortion Jan. 5. 1900 Presented by Dr. Charles Baum.

4835. 09 Missing
4835. 084 Right tube ovary and cyst. Embryo
lies toward the fimbriated end Presented by Dr.
Geo. E. Shoemaker

2318 4835. 30 Extra-Uterine Pregnancy. Pres. by Dr. F.K. Brown
129
3

2319 4835 01 Extra-Uterine Pregnancy Pres. by Dr. J.M. Baldy.
129
3



4800 10 Hydated Cyst.
2272 Pres. by Dr. W.L. Atlee.
127
3

(53)

4805 05 Extra-Uterine Pregnancy.
2273 Pres. by Dr. J.M. Baldy.
127
3.

4800.01 - A SIMILAR SPECIMEN.

Presented by Dr. Mütter

4825 183 Ovarian Cyst
2315 Pres. by Dr. Brysdale
129
3

These are
47 25.1835
42 25.184 Pg. 193

2316 4825 184 Ovarian Cyst. Pres. by Dr. Brysdale.
129
3.

4825.2 -- UMBILICAL CORD. KNOTTED IN UTERO..
2274
127
3
Presented by Dr. W. L. Atlee.

4825.3 Umbilical Cord. Knotted in Utero.
2275
127
4
Presented by Dr. Hinsdale.

4825. -- UMBILICAL CORD WITH 46 TWISTS.
2295
128
3.

This specimen consists of the foetus cord and placenta. This is the largest number of twists on record.

Presented by Prof. Theo. Parvin.

4825.1 Umbilical Cord with 46 Twists -
2279 Presented by Dr. R.P. Harris.
127
5

4835. -- TUBAL PREGNANCY; TUMOR OF THE FALLOPIAN TUBE OF
2317 THE OPPOSITE SIDE.
129
3.

The tumor of the Fallopian tube is about 3 cm. in diameter. The embryo in the opposite Fallopian tube has a length of about 4 cm., and is retained in its membranes. The uterus is slightly enlarged.

Presented. Dr. Mütter

Missing
4835. 05 Extra-Uterine Pregnancy. Presented by Dr. J. M. Baldy.

2331 4835.06 "Tubal Pregnancy. Ruptured; foetus in abdomen. Case of Mrs Parke
130 4835.07 " " " " Dr Noble 11.7.95. 2332.
2. 130
2.

4835.10 -- EXTRA-UTERINE FOETATION; LAPAROTOMY.

Missing

Removed May 18, 1878, from a woman act. 35. The diagnosis of extra-uterine pregnancy was made in April, with the opinion that the child had come to full term in January, when it had died. The

4825.A.
2851
128
5



Foetus and Placenta
Pres. by Dr. Daniel Longaker.

4835 08 Extra Uterine Pregnancy.
2333
130
2.
Pres. by Dr. Shoemaker.



(54)

body was in the lower part of the belly placed transversely, and back forwards, and the head on the left side.

Delivered by laparotomy, through an incision six inches long in the linea alba. Weight 4 lbs. 2 oz. Recovery followed.

Amer.Jour.Med.Sci., Oct. 1878. 76:371

2334
130
2.
4835.11 Ruptured R. Tubal Pregnancy. Foetus.
Presented by Dr. C.P. Noble

2335
130
2.
4835.12 Foetus from an unruptured Tubal Pregnancy of the 6th week.
Presented by Dr. W.L. Goodell.

4835. 20 -- EXTRA-UTERINE PREGNANCY; DOUBLE.
2336
130.
2.

The soft parts have been removed, leaving the agglutinated mass of bones of this imperfectly developed foetus. By accident the second foetus has not been preserved. The anterior surface of the tumor is made up of the occipital bone, the neck and the back as far as the upper dorsal region. The spine is bent at right angles and the dorsum as far as the sacrum and coccyx forms the superior surface of the tumor. The posterior surface extends from the point of the coccyx to the foetal forehead. On this surface can be traced the lower extremities. The hands are placed next the parietal bones. The left wrist is dislocated. The arms are placed on the side of the trunk. The right femur is placed obliquely on the posterior surface. The right leg can be traced across the forehead.

Measurements:-

Bi parietal diameter 3 1/8 in.

| | |
|---|---|
| Antero posterior diameter of mass | 4 5/8 in. |
| Vertex to bend of spine in dorsal region | 4 3/8 in. |
| Dorsal bend to point of coccyx | 4 5/8 in. |
| Left humerus length | 2 in. |
| Right " | 2 1/4 in. |
| Right femur | 2 1/2 in. |

The second foetus was enclosed in the same membrane as the first, and showed no distinct prolongation inwards between the two. Its age was much younger. The head was much flattened, and its bones separated and displaced.

One year after marriage became pregnant; ceased menstruating; noticed enlargement of abdomen. Five weeks before the expected time for labor, abdomen grew smaller. Following this she had four miscarriages and two living children. 24 years after marriage she died in the Medical Department of Penna. Hospital, of diarrhoea and general debility. The specimen was removed, post mortem, from its attachments at the superior straitiof the pelvis, and to the right Fallopian tube.

Presented by Dr. Wm. Pepper.

Vol. vii. Trans. Phila. Path. Soc'y,- p. 102, 1876.

Specimen missing

4835.40 -- FOETAL REMAINS FROM A CASE OF CONGENITAL VENTRAL GESTATION.

2338
130
2.

The specimen was described by Dr. Washington L. Atlee (p.199 "Ovarian Tumors") as follows:

V-missing

4835.36. Abdominal Pregnancy removed at the end of twenty-one months. Foetus at least 7 months
2836 Pres. by Dr. Chas. P. Noble 1.28.03.
128
5

X

4835.37. Extra Uterine Pregnancy.
2835 Pres. by Dr. J. M. Baldy. 3/5/02.
127.
4. V

4835.38 Uterus and Ovaries and Tubes. Extra-uterine
2337. Pregnancy. Foetus .5 inch long.
130 Presented by Dr. John C. DaCosta.
2.

X

4835.39 Uterus and appendages. Tubo-ovarian
2362. pregnancy.
131
2. The foetus is of the month.
The tube ruptured two months before the operation and the patient almost died from the hemorrhage. The sac was torn away from the tube and ovary.

Presented by Dr. J. M. Baldy.

Specimen missing

4835.40 -- FOETAL REMAINS FROM A CASE OF CONGENITAL
2338 VENTRAL GESTATION.
130
2.

The specimen was described by Dr. Washington L. Atlee (p.199 "Ovarian Tumors") as follows:

X its consistence firm, the integument considerably corrugated, probably by the alcohol in which it was kept before dissection.

(56)

The tumor, at first sight, appears to be an amorphous mass;X.....The upper and back portion resembling in structure the scalp, is covered at present with a few scattered, straight hairs. Its size is 3.5 in. in length, and 2 in. in greatest width; weight 2 oz. Anterior to the scalp is an irregular horizontal fissure, supposed to be the rudiment of a mouth. Below this are three perfect temporary teeth, loosely attached to the soft parts or gums of the lower jaw. The exposed and prominent teeth are lateral incisor, bicuspid and molar, resting superficially on alveoli of an imperfect jaw, within the body of which are imbedded one or two rudiments of other teeth seen through an opening at the base. The maxilla has a ridge corresponding with the symphysis. It is movable on the left, but anchylosed on the right side.

"Within the mass I have traced with some difficulty a skeleton, tolerably perfect, though considerably distorted. The cranium, which is large and hard, is united to a short but thick spine; the latter inflexible, curved backward and imperfect behind, constituting the malformation known as Spina bipida, with ridges corresponding to the situation of inter-vertebral cartilage. At the open part of the spinal canal, the cord is distinctly seen giving off filaments. One of these, which I take to be the sciatic nerve, was traced downward to the extremity of the foot. The bones of the head appear

as if fused together; no trace of sutures. There are in it two openings, one in front near the centre, and the other corresponding with the situation of the posterior fontanelle. Each of these openings is about two lines in diameter. A small probe can be passed from one to the other and from either downward through the vertebral canal. The bones of the pelvis are well marked though misshapen, joined at the pubes by a regular symphysis, covered with cartilage; in like manner to the spine. The acetabula are occupied by the cartilaginous heads of the femurs, round and prominent, with tolerably perfect capsules. The left knee and ankle joints are close together, and the foot turned inward. (varus). The right side of the pelvis and right hip joint correspond with the left; but a few lines below the whole extremity appears fibrinous, as if it had been exposed to the action of an acid and had become partially dissolved. The rudiments of the upper extremity were also dissected from the mass, though not so perfectly as the lower, from their smaller size and less prominent position. I could discover no vestige of ribs, nor the pressure of any distinct organs or viscera. Covering the bones is a distinct periosteum."

Removed post mortem from Ann O., aet 6 yrs., who presented in very early childhood an appearance of irregular conformation and enlargement of the

abdomen. An abscess formed in the lower portion of the epigastric and upper part of the umbilical regions, which in time protruded through the abdominal wall, and came away after the application of ligatures. A fistulous opening communicating with the stomach remained until her fourteenth or fifteenth year. The patient died of phthisis pulmonalis at the age of twenty-three.

See Dr. R. P. Harris' report in Trans. Coll. Phys. Phila., 4:231 June 4, 1879.

Presented on behalf of Dr. John L. Atlee,

4835.41 Extra-Uterine pregnancy by Dr. Walter F. Atlee.
Presented by Dr. J.M. Baldy

4845. -- FIBROMYOMA OF THE UTERUS, COMPLICATING PREGNANCY.

2306
128
5.

The specimen shows a gravid uterus at 6 mos.; opened so as to show the foetus in situ. To the fundus of the uterus an enormous fibroid tumor is attached by a broad and strong pedicle.

For this complication of pregnancy, and for the probability of great interferance with labor, the uterus and contents, and the attached tumor, were removed by abdominal section. Death on the third day.

Presented by Dr. J. Ewing Mears.

4850. --

4850. -- CERVIX UTERI; SEVERED DURING LABOR.

2363.
131.
2.

From Mrs. P., aet. 28. For two months previous to the normal term of pregnancy, she had suffered from violent spasms of the womb. A dead child was delivered during the temporary absence of the medical attendant. Am examination then showed that the whole vaginal portion of the cervix uteri had been torn off, and was suspended only by a pedicle protruding from the vagina. This was ligated and detached.

The patient made a good recovery, notwithstanding several hemorrhages. The ligature came away in four weeks. Sixteen months later she was confined and had a normal delivery.

Presented by Dr. Kellar.

4866. -- VULVA AND RECTUM. RECTO-VAGINAL FISTULA.

2365
131
3.

The fistula is about 2 cm. from the outlet. Strands of silk have been passed through the fistula and tied outside.

Presented by Dr. Corse.

4866.10 -- RECTO-VAGINAL FISTULA.

2366
131
3.

Presented

4885.
2364.
131.
2.

Pres. by Mr. W. S. Atlee.

Write history from card





(60)

4866.20 -- FEMALE GENITO-URINARY ORGANS. RECTO VAGINAL FISTULA (?) SCIRRHUS UTERI.

2278
127.
4.
2350
130
5.
4870
4885

Fibroma of the uterus complicating Pregnancy; foetus in situ. Retained Placenta Presented by Dr Joseph Price.

The placenta is contracted, hardened and black at its margins. Menstruation ceased in March. This expelled in Dec. after use of Ergotine. Presented by Dr W. F. Atlee.

4892. -- FOETUS; CRANIOTOMY.

4885

Mrs Mc N - aged 25 - married in January 1889 - bore a child on July 4th 1890, that lived but two days. Her menstruation ceased in March 1891, and she believd herself to be again pregnant. She never menstruated afterward, yet became only slightly larger. I was consulted on Dec. 9th, and believing her to be suffering from a uterine growth, put her upon the use of Ergotine; giving a grain, an hour after meals. On the 16th Dec. this specimen was expelled.

(Copy.)

Walter F. Atlee.

Material now on card in f. 1a.

4885.
2364.
131.
2.

Pres. by Mr. W. S. Atlee.

Write history from card



4866.20 -- FEMALE GENITO-URINARY ORGANS. RECTO VAGINAL FISTULA (?) SCIRRHUS UTERI.
2278
127.
4.
2350
130
5.
4870
4885

Fibroma of uterus complicating Pregnancy; foetus in situ.
Retained Placenta Presented by Dr Joseph Price.

The placenta is contracted, hardened and black at its margins. Menstruation ceased in March. This expelled in Dec. after use of Ergotine.
Presented by Dr W. F. Atlee.

4892. -- FOETUS; CRANIOTOMY.

This foetus, 60 cm. long and in weight, was delivered by craniotomy from a woman in her fourth pregnancy with contracted pelvis, at whose previous deliveries similar means were used. Recovery followed.

Trans. Coll. Phys. Phila. Vol.III, n.s., p.196.

Presented by Dr. J. M. Corsle. April 7 - 1858

4897. -- ABNORMAL PRESENTATION.
2367.
131
3.

The foetus presents by its shoulder and back; a band has been placed around, so as to obtain the form as presented.

4910. Mammary Tumor. Anonymous.
2299 Pres. by Dr. Mutter.
128
4.

4910.0 -- MAMMARY TUMOR.
~~664~~
~~50~~
2280.
127.
5

Presented by Dr. Mütter.

4910 11. Mammary Tumor.
2298
128
3.
Pres. by Dr. Mütter Missing

4910 12. Mammary Tumor.
2300
128
4.
Pres. by Dr. Mütter

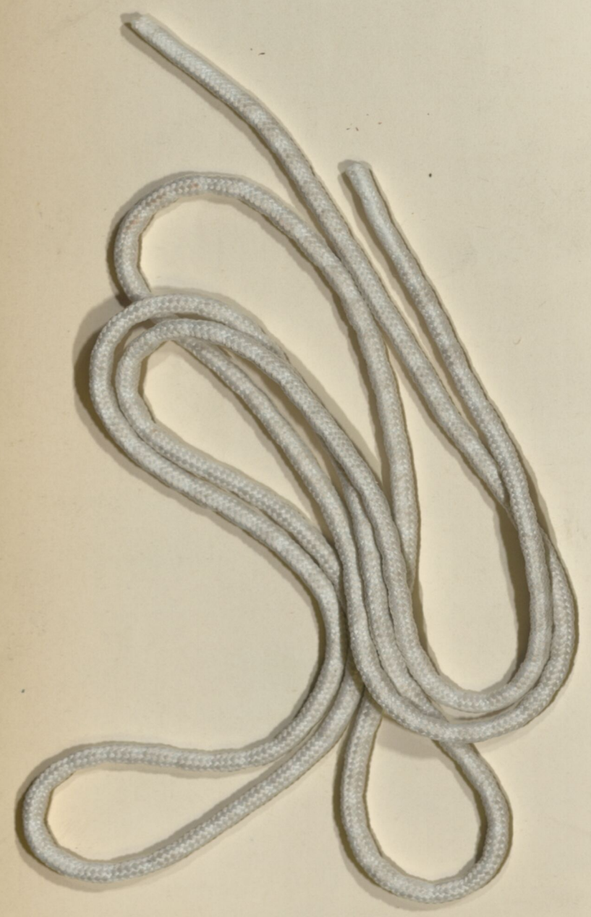



4910.05 -- MAMMARY TUMOR.
2281.
127.
5.

Presented by Dr. Mutter.

4910.10 -- MAMMARY TUMOR.
2282.
127.
5.

Presented by Dr. Mutter.

4910.15 -- MAMMARY TUMOR.
2301
128
4.

Presented by Dr. Mutter.

4910.20 -- MAMMARY TUMOR.
2302
128
4

Presented by Dr. Mutter.

4910.25 -- MAMMARY CANCER.
2303.
128
4.

Removed from an unmarried woman, aet. 44 yrs., of twenty months duration. Menstruation ceased with the commencement of the growth, June, 1864.

Presented by Dr. W. L. Atlee.

4910.30 -- MAMMARY TUMOR.
2304
128
4.

Presented by Dr. Mutter.

2320
129
4.

4910.31 Mammary Cancer. Presented by Dr J.C. Da Costa.

4910.35 -- MAMMARY TUMOR.

2321
129
4.

Pres. by Dr. Mutter.

4910.40 -- MAMMARY TUMOR. Storeroom case 1 - Bottom shelf

2322
129
4.

Pres. by Dr. Mutter

4910.45 -- MAMMARY TUMOR.

2323
129
4.

Presented by Dr. Mutter.

4910.48 -- MAMMARY TUMOR.

2324
129.
4.

Presented by Dr. Mutter.

4910.50 -- MAMMARY TUMOR.

2344.
130
4.

Presented by Dr. Mutter.

4910.52 -- MAMMARY TUMOR.

2345
130
4.

Presented by Dr. Mutter.

4910.54 -- MAMMARY TUMOR.

2346
130
4.

Presented by Dr. Mutter.

4910.51 Mammary Tumor.
2570
137
6.





Missing
4910.56 -- MAMMARY TUMOR.
2347
130
4.
Presented by Dr. Mutter.

4910.58 -- G. 244 MAMMARY TUMOR.
2348
130
4.
Presented by Dr. Mutter.

4910.60 -- G.247 MAMMARY TUMOR.
2349.
130
4.
Presented by Dr. Mutter.

4910.62 -- G.248 MAMMARY TUMOR.
2368.
131.
3.
Presented by Dr. Corse.

4910.64 -- G.249 MAMMARY TUMOR.
2369
131
3.
Presented by Dr. Mutter.

4910.65 Mammary Tumor " " " Drysdale.
2370
131
3.
Missing
4910.66 -- G.251 MAMMARY TUMOR.

Left mamma removed from a woman aet. 59,

March 19, 1866. Duration, one year.

Presented by Dr. W. L. Atlee.

2379
131
5.
4910.67 Mammary Tumor " " " T. M. Drysdale
2371
131
4.
4910.68 " " " " " " " "
2372
131
4.
4910.69 " " " " " " " " wt 12 lbs.
4910.70 " " " " " " " " 2373
131.
4.
G.251 -- MAMMARY TUMOR.
4910.72 Missing

Presented by Dr. Mutter.

✓ missing

4918.10 -- MAMMARY SCIRRHUS.

Presented by Dr. Mutter.

2374 4918." ✓ Scirrhus of the breast " Drysdale.
131
4

4918.12 Scirrhus of the Right Breast.
2375 Removed from Mrs C.S.H. By Dr Drysdale Mch. 16, 1898
131
4. Presented by Dr. Thu. Drysdale

4918.13 ✓ Carcinoma of right breast and mammary
2376 glands Removed from Mrs. W.a. L by Dr Drysdale
131
4. Mch. 30. 1898. Presented by Dr. Drysdale.

(?)

~~4918.14~~ ~~Slough of Cancerous Mamma produced~~
2377.
131
~~4. by Escharotics applied by a quack doctor~~
~~after three months of agony, the slough,~~
~~not separating, was cut away April 2. 1898~~
~~Presented by Dr.~~ Thu. Drysdale

NERVOUS SYSTEM.

335

5001.
2380
132
1.

# Porencephalon.

Case of G. P., aged seven years. He had bilateral spastic hemiplegia of cerebral origin. His right arm especially was spastic and contractured, and the seat of athetoid movements. The legs also were spastic, and the patellar reflexes were exaggerated; ankle clonus was well marked on the left side, but not on the right. The child had but little ability to walk; his legs doubled under him, and he had a tendency to rise on his toes. He had internal strabismus. His mental condition was slightly impaired. His general physical condition was good. The muscular development of the legs was perfect. There was no anæsthesia or atrophy. His head was evidently asymmetrical but there were no scars or depressions upon it. Very little history of the case was known, as, for instance, whether the child had had any trauma or any of the eruptive diseases. Nothing was known of his birth or whether he had had convulsions. About one month after admission, however, he had a series of severe convulsions, after which the athetoid movement in the arm was increased. No signal symptom was noted for lack of opportunity to observe the fits. After each convulsion the child's mental faculties were perceptibly weakened. He was dull and listless, with increased athetoid movements in his arms for some hours or days. An examination of the eyes by Dr. de Schweinitz revealed normal pupils with convergent strabismus, the left eye being used preferably for fixation; fundi, with exception of absorption of pigment epithelium of the choroid, showed no abnormalities; high myopia.

The circumference of the child's head was $19\frac{1}{16}$ inches; of the left side $9\frac{9}{16}$ inches; of the right side $11\frac{2}{16}$ inches. The prominent symptoms of the case were thus seen to be a local athetoid movement confined to the right arm, with severe epileptic attacks, increasing for some hours the athetoid condition and impairing the child's mental faculties. After two months' observation, during which time the child's course was progressively downward, a consultation was held ~~with Drs. Willard~~, and an operation done by Dr Willard. On the Eighteenth day the patient died of Scarlet fever.

The autopsy was made a few hours after death. The brain showed not a trace of septic infection. There was no meningitis. The wound was aseptic although it had not healed at all the needle-points. The body presented nothing of special interest, except the brain, which alone will be described. The left hemisphere presents an immense porencephalon. This porencephalon involves the Rolandic region. It extends anteriorly beyond the pre-frontal fissure, downward almost or quite to the operculum; backward to include the superior parietal lobule; in other words its area coincides very closely with the distribution of the middle cerebral artery, the superior convolutions of the temporal lobe alone having escaped. Its edges and sides are formed of the convolutions of the brain which have sunk downward and still preserve, especially in the anterior part, their form and relative positions. In the mid-region of the cavity is a large crater-like opening, extending into the lateral ventricle. The membranes at the edge of the cavity are shrivelled up, and form a distinct line or ridge, separating the cavity from the surface of the brain. The gray matter of the mesial aspect of the brain is atrophied and almost destroyed. The gyrus fornicatus is preserved. The left hemisphere is smaller than the right. ~~The measurement from the tip~~

See Amer. Jour. Med. Sci. April 1892.

Presented by Dr Jas. Hendrie Lloyd.

103: 381

273
335

P. 273 b



There was still no discharge from the bowels, and I recommended the repetition of the calomel and soda powders during the forenoon with another dose of oil and turpentine in the afternoon; and in case of no evacuation to resort to another enema of warm water with castor oil and spirits of turpentine in the night.

An effort was made to get colleagues from the city to see the patient during the day, with a view to a conference as to the surgical treatment that might be warranted, but owing to engagements of a pressing nature, neither of those to whom I applied was able to go, and the meeting was deferred until next morning, the fifth day of this disorder.

A conference with W. S. Elkin, G. G. Roy, and W. D. Bizzell, during the forenoon of the 11th, resulted in a conclusion not to undertake any operative measure, owing to the great vital prostration of the patient and the occurrence of a fluid fæcal evacuation about nine o'clock a. m.

In undertaking to administer chloroform, with a view to a more thorough manipulation of the abdomen than was admissible on account of the extreme sensitiveness to the touch, there was such manifest depression of the vital powers, with feeble pulse of 120 beats and temperature normal, as to cause us to desist from the inhalation of the anæsthetic, and to abandon the thought of an exploratory puncture over the ileo-cæcal region in search of pus in the deep structures, there being no fluctuation.

Brandy with milk and beef-tea was given freely internally, the hypodermic injections of morphia and atropia were continued to relieve restlessness, and a blister of cantharides plaster was placed over the belly.

Having left the patient in this most unpromising condition at 1 o'clock p. m., I received a message by telephone shortly after 5 p. m. that he had expired a few minutes previously.

Realizing that the proper understanding of the progress and result of this case rendered it important that an autopsy should be made, I prevailed upon my colleague and friend, Dr. R. C. Wood, the father of the patient, to intercede with his family for a post-mortem examination, which was granted.

Dr. W. S. Elkin assisted me in making the autopsy at 9 o'clock on the morning after his death, and I ventured to predict before the body was opened what might be expected, which diagnosis was confirmed by the results as here reported.

Upon laying open the abdomen along the linea alba, and making a transverse incision from the umbilicus to the right anterior superior spinous process, recent adhesions of the intestines to each other and to the peritoneal lining of the abdominal walls, indicated general peritonitis. On exposing the ileo-cæcal region, the cæcum was found covered with exudation, and presenting a dusky reddish dark hue, while the vermiform appendage was much thickened and discolored with a perforation about midway its length, and a large bean impacted near its connection with the cæcum, but its immediate entrance into the wall of the cæcum seemed to be comparatively free from turgescence or engorgement.

The portion of intestine below this knuckle was relaxed and empty, while that above was distended with gas, and yet the bowel was not completely occluded from the inflammatory thickening of its coats, but was rendered impervious by the angular relation of its walls. It will be remembered that in my report of a case of laparotomy some months ago, this doubling of the intestine upon itself was referred to as intercepting the passage of even gaseous matters through it in the same way that an India-rubber tube becomes occluded by being flexed at a sharp angle. The thickening of the coats of the ileum in connection with this flexion had been sufficient to arrest any free transit, and yet doubtless admitted of the passage of the fluid fecal matter which was discharged spontaneously on going to stool some eight hours before death. As there was no strangulation of the bowels, we are prepared to understand the absence of vomiting, which was inexplicable upon the supposition of intussusception or other entire constriction.

There was some effusion in the peritoneal cavity, but the undertaker had already thrown into the abdomen an antiseptic fluid before it was determined that an autopsy would be made, and hence no estimate could be made of the amount or nature of the exudation. It was evident, however, that the contents of the appendix vermiformis had escaped through the perforation and caused the general peritonitis.

The key to the peritonitis and to the vital depression from septicæmia was exemplified by the occlusion and perforation of the vermiform appendage, and a constriction in the ileum explained the obstruction, the gut being bent upon itself and much inflamed where it lay against the appendage. As has been stated, my diagnosis was verified by the autopsy, but unfortunately I had not the data for making this diagnosis until it was too late to accomplish what might have been

273
335
p. 273a



attained at a very early stage of this case by laparotomy.

The members of the medical profession who have had most experience in abdominal surgery and in diagnosticating the causes of intestinal obstruction will appreciate the difficulties in the way of a differential diagnosis within the first three days of the course of this case. While my attention was early fixed upon the cæcal region as the source of trouble, it was only after the indications of a septic nature and the consequent depression of the nerve centres, that I realized the probable existence of perforation of the vermiform appendage. At this stage of vital prostration there was no reasonable ground to expect any other than a fatal result of laparotomy; and no surgeon is warranted in operating under such untoward surroundings as were presented during the last thirty-six hours of the waning life of this patient. It is highly probable that laparotomy within the first twenty-four hours and excision of the entire vermiform appendage with suture of its line of separation, would have been attended with success. But with only such symptoms as accompany typhlitis of an aggravated character to guide my steps at that stage of development, I did not consider, nor do I now think such operation warrantable at this period of an unforeseen complication of intestinal obstruction.

---

## ON EPILEPTIC BRAINS.*

BY FRANCIS X. DERCUM, M. D.,

Instructor in Nervous Diseases, University of Pennsylvania, and Pathologist to State Hospital for the Insane at Norristown.

The writer has thus far had the opportunity of studying twelve epileptic brains. Eleven of these have been already described in the "Report of the Pathological Laboratory of the State Hospital for the Insane at Norristown" for the current year, while the twelfth has likewise been described in the "Pathological Report" of the same institution for the year 1885.† It is not, therefore, my intention to give a detailed account of the convolutions of these brains, but merely to point out some striking peculiarities and to give expression to some of the thoughts which this study has suggested.

We have, in the first place, a notable tendency to the confluence of fissures, which is an acknowledged point indicating a low degree of cerebral development. This tendency is well marked in *every one* of the brains studied. In a number of instances the fissure of Rolando is confluent with the Sylvian fissure. In a number of others the Sylvian, interparietal, and parallel fissures are variously confluent. One of the most striking and most constant instances of confluence is observed in the parieto-occipital with the interparietal. It occurs completely in *seven* of the brains studied, and imperfectly in two others.

This tendency to the confluence of fissures is of necessity accompanied by an absence or lessened development of the normal arching or bridging convolutions. For instance, as is well known, the upper end of the parieto-occipital fissure is normally separated by the first occipital convolution of Ecker, the so-called *pli de passage supérieure externe* of Gratiolet. In the instances where these fissures are confluent this *pli de passage* is either entirely absent or so imperfectly developed as not to emerge upon the general surface of the brain.

As a result of the confluence of fissures, appearances resembling the conditions found in the brains of monkeys are occasionally simulated. This, again, is notably the case where the parieto-occipital and inter-parietal fissures are confluent. In the majority of instances in which this confluence occurs, the upper end of the parieto-occipital passes through the inter-parietal fissure, and terminates far beyond on the lateral surface, thus exactly reproducing the *external perpendicular fissures of the apes*. Occasionally this external perpendicular fissure is accompanied by a second fissure running in a parallel direction, and in one of the brains studied there were three such parallel external perpendicular fissures. It is probable that in these cases *one* of the fissures is homologous with the corresponding fissure in the apes, while the others are merely "*vegetative repetitions.*"*

Following the course of the external perpendicular fissure we come, in some instances, upon a well-marked Wernicke's fissure—*i. e.*, a fissure running more or less perpendicularly and separating the occipital and temporal lobes. In one of the brains the external perpendicular fissure and the fissure of Wernicke are so well developed that the occipital lobe is, as it were, almost lopped off from the rest of the brain.

In addition to such fissures as appear to

*Read before the Philadelphia Neurological Society, December 27, 1886.

†Also more fully in the proceedings of the Pathological Society of Philadelphia for 1885.

*The reader is referred to a communication by Dr. A. J. Parker published in the proceedings of the Academy of Natural Sciences, 1878, in which the *principle of* "*vegetative repetition*" of fissures and convolutions is pointed out.

p. 273c



half a milliampère. Therefore if I state I have used eight cells, it means generally four milliampères. This calculation varies somewhat according to other influences, but particularly according to the internal and external resistance. Good instruments which measure exactly, without fail, are too costly to be used ordinarily by the practitioner of medicine.

The *modus operandi* is usually as follows. After the patient's history has been taken, the topography of the urethra should be well ascertained and the strictures measured,—how small they are, how many, and the distance from the meatus at which they are located.

The exploring instrument transmits to the fingers certain sensations, which experience soon classifies, and which culminate in a high tactile expertness. I use for the purpose a whalebone *bougie à boule*, which has a small olive-shaped head and slender neck; this adds to its flexibility. Such an exploring instrument gives, from its peculiar shape, a delicacy of touch not to be obtained by any other known bougie. It defines with scientific exactness the nature of the stricture; the progress of altered tissue can be ascertained and defined by it with a comparatively small experience and with great certainty.

Assuming that the diagnosis has been made and the preceding means employed in order to ascertain the condition of the stricture, certain sensations will be revealed by touch; and in order better to comprehend this I may compare them with some well-known material, such as a feeling of velvet or velveteen, of paper, of parchment, or of cartilage.

In the normal state of the urethra the bougie glides with comparative ease over its moist mucous lining. The skilled finger will readily detect any alteration or deviation, its relative and comparative severity, and the slightest encroachment on its normal standard will be revealed. The velvet touch represents a slight alteration only.

For ocular inspection of the urethra I have always used the endoscope, when necessary.

The patient's susceptibility to the galvanic current is to be learned by applying it to his hand or some other part of his body. The posture which the patient should assume during the operation is a matter of slight importance: according to his convenience, he may stand, sit, or lie on his back with his shoulders elevated and his knees drawn up. Anæsthetics are not used, because no pain should be caused, and because the patient ought to be conscious, so that he can express his sensations. For ordinary strictures, the size of the bougie selected should be three numbers (French) larger than the stricture.

The fluid of the battery should not be made too strong.

The elements of the battery are immersed in the fluid, the slide standing at zero.

The electrode is well greased with glycerine, which is a good conductor.

Having ascertained by actual measurement the locality of the stricture or strictures (if there be more than one), I push a small india-rubber ring over the bougie for each of them. This little manœuvre has many advantages: not the least important is that I am made aware as soon as the india-rubber ring arrives at the meatus that the extremity of the bulb must be in contact with the stricture.

Having the plan of the urethra from actual measurement before me, I operate with additional certainty, and beyond a peradventure as to the part which is acted upon.

This bougie electrode is then introduced into the urethra until the bulb is arrested by the stricture. A sponge electrode, wet with warm water and connected with the positive pole of the battery, is then held firmly against the patient's skin (best in the palm of the hand or pressed against the abdomen, the thigh, or some other part), to complete the circuit. While both poles are held in this manner, the current is to be increased very slowly and gradually, one cell at a time, until the patient feels a warm and slightly pricking sensation. The operator should keep the bougie steadily against the stricture, and he will soon find absorption taking place, the stricture yielding, dilating, and the instrument slowly advancing and passing the obstruction: at times it fairly jumps through the stricture. If there are more strictures than one, the bougie should be guided in the same way until it enters the bladder. Then the electrode is to be withdrawn slowly, and each stricture well worked out until the first stricture is passed, when the current is again to be reduced slowly, cell by cell, to zero; and not until then is the electrode to be removed. During the whole operation the electrode must be held

loosely and gently in its place against the obstruction, all pressure or force being avoided. The bougie will take care of itself, doing its work by the electrolytic action of the current. A *séance* might last from five to twenty minutes.

The observance of the following rules would conduce to success:

1. Begin the use of electrolysis carefully, not cauterizing, but only causing absorption, six cells being enough in many cases, or a current-strength of two and a half to five milliampères.

2. Regulate the current according to the susceptibility of the patient.

3. Repeat the *séances* at intervals of three or even four weeks, the shorter intervals being exceptional.

4. Do not lubricate the electrode with a non-conducting substance.

5. Wet the sponge electrode with hot water.

6. Keep the plates in the battery-fluid only during the operation.

7. Never use force with the bougie; never cause hemorrhage.

8. Do not operate while the urethra is in a state of acute or subacute inflammation, or when the application causes pain.

9. Do not use the battery-fluid too strong.

10. Never use two bougie electrodes in succession at one *séance*, or follow the bougie with any other instrument.

11. Do not push the bougie to and fro in the urethra; it must be passed only once down and back again, and that with care.

In conclusion, I will merely say that all urethral strictures are amenable to this treatment by electrolysis, but the great advantages of this treatment I cannot discuss, as the hour has expired.

68 West Thirty-Fifth Street, New York.

## ORIGINAL COMMUNICATIONS.

5050.

### DESCRIPTION OF THE BRAIN OF JOHN M. WILSON, RECENTLY HANGED AT NORRISTOWN.

*Read before the Philadelphia Neurological Society*

BY FRANCIS X. DERCUM, M.D.,

Pathologist to the State Hospital for the Insane at Norristown; Instructor in Nervous Diseases in the University of Pennsylvania.

THE brain came into the possession of the writer accompanied by a portion of the dura mater and the other enveloping membranes. Drs. R. H. Chase and Henry Sykes made a verbal report to me in reference to the skull. In the first place, the head was unusually large, while the face was disproportionately small. On opening the cranium, over six ounces of cerebro-spinal fluid escaped. The bones were very thin, and the sutures all completely fused. The dura was thickened and decidedly adherent to the inner surface of the calvarium, thus giving evidence of external ossific pachymeningitis. The pia was thickened, loose, and excessively œdematous. Its meshes were everywhere filled with fluid. In addition, it was injected and presented numerous milky opacities, such as are not infrequently found in alcoholic subjects. On the mesial surfaces of the hemispheres the two opposed layers of the pia, where not separated by the falx, were everywhere coherent, thus showing positive inflammatory change.

The two hemispheres were unequal in size, the left being much the larger. The lateral ventricles were somewhat dilated, and their walls excessively pale, as were also the walls of the third ventricle. The white substance of the brain, too, was likewise unusually pale, though here and there some of the smaller vessels appeared injected, probably due to the mode of death. The velum interpositum was infiltrated. The pineal gland was large and œdematous.

The brain throughout was exceedingly soft. The crura, pons, cerebellum, and medulla partook in general of the character of the hemispheres.

The brain—all fluid having been allowed to drain away—was weighed, the weight equalling fifty-seven and a half ounces. Its great size was very striking.

The most interesting feature, however, in connection with this examination was the study of the convolutions. Taking up, to begin with, the left hemisphere and studying its lateral surface, we notice at once an unusual degree of confluence between various fissures, and also the presence of a large number of abnormal fissures. For instance, the fissure of Rolando is superficially confluent with the Sylvian, being separated from the latter by the merest strip of tissue. The precentral fissure is freely confluent with the Sylvian. The interparietal is confluent with a small transverse fissure cutting deeply into the *pli de passage supérieure*

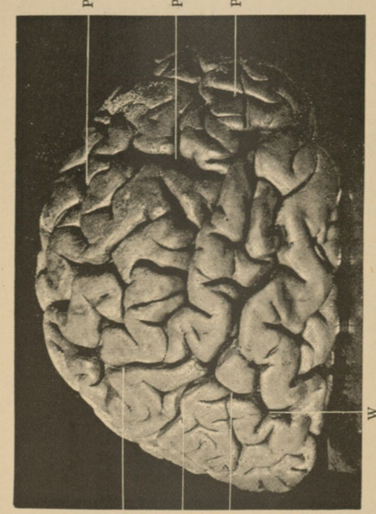


RIGHT HEMISPHERE.—LATERAL SURFACE.

EP = external perpendicular fissure. EP' and EP'' = vegetative repetitions of EP. W = Wernicke's fissure. As in the left hemisphere, EP and W constitute an arc. PC = precentral fissure. PC' and PC'' = unusial precentrals (vegetative repetitions). In advance of W is a short perpendicular fissure which suggests a second Wernicke.

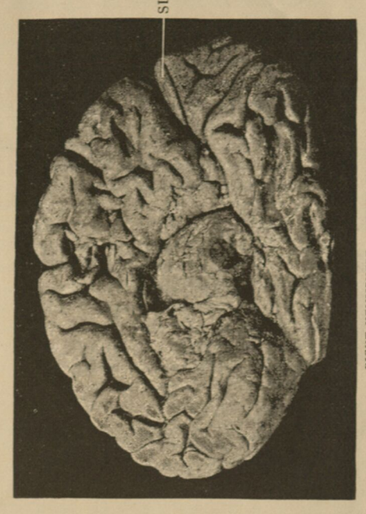


RIGHT HEMISPHERE.—MESIAL SURFACE.

SIP = superior internal *pli de passage*.

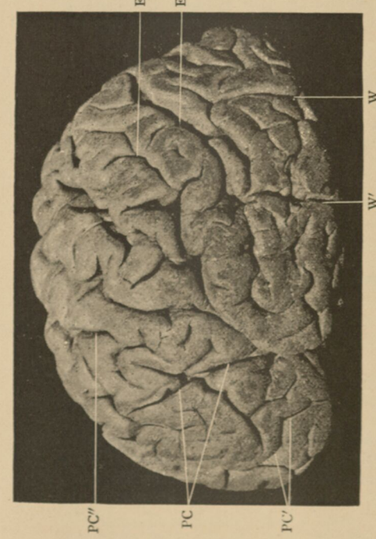


LEFT HEMISPHERE.—LATERAL SURFACE.

PC = precentral fissure. PC' and PC'' = unusual precentral fissures. EP = external perpendicular fissure. EP' and EP'' = vegetative repetition of EP. W = Wernicke's fissure. W' = vegetative repetition of W. EP and W, taken together, form an irregular arc. EP' and W' also suggest an incomplete second arc.

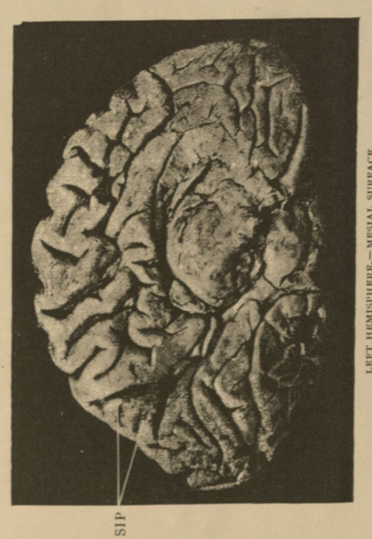


LEFT HEMISPHERE.—MESIAL SURFACE.

SIP = superior internal *pli de passage*.

273

335

p. 273 f



*externe*, and evidently a detached portion of the parieto-occipital fissure. This is an ape-like characteristic. Other evidences of confluence can be seen in the parallel fissure, which is confluent with a number of perpendicular fissures.

Some of the abnormal fissures of the lateral surface are of morphological significance; others must be regarded as purely pathological. Studied from before backward, they are as follows. First an abnormal perpendicular fissure close to the apex of the frontal lobe. It starts from the anterior portion of the third frontal convolution, which it incises; then passes in a more or less perpendicular direction upward, prevents the normal development of the second frontal fissure, cuts deeply through the second frontal convolution, and finally fuses with the first frontal fissure. Secondly, the fissure occupying the position of the normal precentral fissure presents a very unusual appearance. A fissure confluent with the Sylvian passes upward and joins as normally the second frontal fissure. At this point, however, it becomes more like a cleft than a fissure, and deeply incises the second frontal convolution, becoming all but confluent with the superior frontal fissure,—is in reality superficially continuous with it. Again, at the point of junction with the second frontal fissure, two abnormal fissures arise, one passing obliquely downward into the operculum, the other obliquely upward and backward into the posterior portion of the second frontal convolution. An irregularly stellate arrangement is thus produced.

As occasionally found in other brains, the superior frontal fissure is confluent with a perpendicular fissure, really a precentral fissure, just in front of the fissure of Rolando. It is large and deep. We thus have in this frontal lobe three well-marked perpendicular or precentral fissures. The significance of this fact will be presently discussed.

The parietal, temporal, and occipital lobes also present a number of remarkable fissures, all of them having a more or less perpendicular direction. For instance, directly opposite the parieto-occipital fissure is found an external perpendicular fissure, homologous doubtless with the corresponding fissure in the apes. It runs obliquely downward, and in the lower portion of its course it is confluent with the parallel. In advance of and pursuing a similar direction to this fissure, and separated from it by what is apparently the angular gyrus, is another perpendicular fissure. It separates the angular gyrus from the supra-marginal lobule, is shallow and blind at both ends, though at first sight it appears as though confluent with the Sylvian. It is doubtless a "vegetative repetition"* of the first-mentioned perpendicular fissure.

A deep and well-marked Wernicke's fissure is present. It pursues an almost perpendicular course downward, immediately beneath the first-mentioned external perpendicular fissure. Strange to say, in advance of it—parallel to it, though separated from it by a large block of tissue—is found another vertical fissure, corresponding doubtless to the above second-described external perpendicular fissure, and, like it, a "vegetative repetition." This fissure deeply bisects the temporal lobe, and is confluent with the parallel.

On the occipital lobe the interparietal terminates, as normally, in a transverse occipital fissure, and below this a parallel "vegetative repetition" (a second occipital fissure?) is found.

The mesial surface of this hemisphere, upon being examined, proves no less interesting. The calloso-marginal fissure is more complex than usual by a tendency to confluence with fissures pursuing transverse or perpendicular directions. The quadrate lobule is large, and contains an unusually deep, irregularly H-shaped fissure. The most remarkable feature of the mesial surface, however, is that the parieto-occipital fissure is bifurcated. This bifurcation is produced by the development of a highly aberrant convolution, the *pli de passage supérieure* INTERNE of Gratiolet. This remarkable convolution the writer had never seen developed to the surface in any human brain, with the single exception of that of an epileptic; in which, however, it was comparatively small. This internal superior *pli de passage* is normally developed in the anthropoid apes, notably the chimpanzee. In the present instance it has the shape of a large equilateral triangle, encroaching markedly upon the cuneus. The latter is relatively small. The calcarine is long and sinuous, and termi-

* See Proceedings of the Academy of Natural Sciences, Philadelphia, 1878. Communication by Dr. A. J. Parker.

p. 273g



nates without bifurcating on the apex of the occipital lobe. It is superficially confluent with the fissura hippocampi, as the gyrus fornicatus is at this point submerged. Beneath the calcarine is found a shallow "vegetative repetition." A deep collateral fissure is present.

The right hemisphere resembles in a general way the left. It differs, however, as follows. In the first place, the tendency to transverse fissuration, so well marked in the left hemisphere by the presence of three (precentral) perpendicular fissures, is much less pronounced on this side. A faint depression alone marks an analogy to the first precentral fissure of the other hemisphere; the second (the normal) precentral is not confluent with the Sylvian, and, though deep, is not by any means as complex as its fellow on the opposite brain; while a third precentral, though present, is much smaller than its opposite fellow.

The fissure of Rolando is superficially and irregularly confluent with the Sylvian. The fissure of Sylvius, though short, presents nothing worthy of note beyond a superficial confluence with the anterior portion of the interparietal. The latter, with the exception just mentioned, giving off a small retro-central branch, pursues an average course, winding around an unusually large *pli de passage supérieure externe*, and finally terminates in a small transverse occipital. The parallel fissure is remarkable for being confluent with no less than three external perpendicular fissures. The middle and principal one of these arises opposite the parieto-occipital fissure, and, passing downward and forward, becomes confluent, as just stated, with the parallel. The one anterior separates, as upon the opposite hemisphere, the angular and supramarginal convolutions. It is also deeper than its opposite fellow. It runs directly downward, and is confluent with both the interparietal and parallel fissures. The third and posterior runs downward and forward, approaching more nearly a horizontal direction. It is deep, but terminates superficially in a well-marked Wernicke's fissure. This last-mentioned fissure is remarkable for being *directly continuous* with the middle or principal external perpendicular fissure. By this means the occipital lobe is sharply demarcated from the parietal and temporal lobes, thus reproducing the condition found in the apes.

Upon the mesial surface the same tendency is observed, as in the opposite hemisphere, of confluence of the colosso-marginal fissure with transverse or perpendicular fissures, though it is here less marked. The quadrate lobule again is very large, and marked by unusually deep stellate fissures. As upon the opposite side, the parieto-occipital fissure is bifurcated. A superior internal *pli de passage* is present, though it is very much smaller than upon the opposite side. Strangely enough, the superior external *pli de passage* is relatively very large on this side, whilst upon the opposite hemisphere, in which the *internal* convolution is so large, the *external* convolution is relatively small. The cuneus is a trifle larger than upon the opposite side. The calcarine is smaller, and less sinuous, but terminates without bifurcating, as in the opposite brain. The calcarine, however, *passes directly into the fissura hippocampi*, the gyrus fornicatus being here entirely absent. This is another striking ape-like characteristic.

In taking a general glance at this remarkable brain, it is evident, as pointed out by the writer in a recent paper on "Epileptic Brains," that two powerful factors have combined to produce this distorted and aberrant organ. In the first place, there was in this brain a distinct morphological factor: that is, the line of development, instead of following the direction usual in the human brain, was deflected early in its course, so as to reproduce more or less perfectly structures and conditions found in the apes. The term "arrest of development" will hardly cover the production of ape-like structures such as instanced in the superior internal *pli de passage*. It seems, indeed, as though arrest of structure in one part necessitated the hyperdevelopment of some other part. Now, forcible arrest of growth readily presents itself as an interfering or deflecting cause. Let us reflect a little further, and the difficulties may solve themselves.

What is the meaning of this thin, large, and dilated skull? What is the meaning of this transverse fissuration of the brain? Evidently the two go hand in hand. Evidently this large, excessive brain-mass developed under pressure, and transverse clefts, most marked at the two poles of the brain, were the natural result. But is this all? Why does this transverse fissuration simulate so closely the fissuration found in the apes? Evidently those areas of the cerebral cortex in man which most distinguish him from the ape are of *late*—of *recent*—development. They represent, therefore, areas in which the developmental force, or growth-force, is relatively weak. Given, then, an interfering or repressive cause, these areas are the first to yield to the stress of circumstances. They remain undeveloped. *Their very absence, however, necessitates the reproduction of other portions, portions long disused, and therefore rudimentary or absent in the normal state.* In this way the writer would explain the production of such a wonderful structure as that represented in the *pli de passage supérieure interne* of this brain.

If this view be correct, the pathological factor is, after all, dominant, and in the present instance the condition of the skull and the evidences of inflammatory changes in the membranes certainly help to bear it out, as does also the microscopic examination. Sections were prepared by Dr. Ida V. Reel. They were taken from the paracentral lobules of either hemisphere. They show, in certain portions of the white matter, decided increase of the neuroglia, dilatation of the perianglionic lymph-spaces, with consequent or concomitant shrinking of the cells, an increase in the number and tortuosity of the vessels, here and there a capillary with its walls infiltrated with nuclei, and sometimes a dilated perivascular space. In one and the same section, however, are found cells which present nothing abnormal whatever. Doubtless enough of such tissue was present to maintain cerebration.

The writer refrains from making comments on the mental condition of the possessor of such a brain. He does not, however, believe that any one with a full knowledge of the facts would predicate of such a brain a normal mind, and yet such an individual might be perfectly able to appreciate the consequences of crime, to differentiate between right and wrong, and to be, in the eyes of the law, a responsible individual. With this, however, the pathologist has nothing to do.

---

THE HOSPITAL OF THE JEFFERSON MEDICAL COLLEGE has just come into possession of a bequest of a hundred thousand dollars, through the hands of Professor William S. Forbes, who for several years had held the amount in trust from the estate of the late Mr. Louis Audenried, of Philadelphia.

273

335

p. 273h



## THE DUTY OF THE STATE TO THE INSANE.

*Read at a joint meeting of the Philadelphia Neurological and Medical Jurisprudence Societies, January 24, 1887,*

BY EDWARD N. BRUSH, M.D.,

Senior Assistant Physician, Pennsylvania Hospital for the Insane, Male Department.

THE embarrassment of my situation this evening will, I hope, be appreciated, and the crudity of my remarks be excused, when I say that only five days ago was I made aware that a paper was expected from me.

The subject which I have chosen is one to which I have given some thought and investigation, but the time has been too brief to place my ideas in orderly relation to each other, or to gather the scattered host of authorities and references which I might otherwise marshal to my support.

What I have to present, therefore, is thrown out more with the hope of provoking discussion and interest in the subject than with the idea of enlightening any of the members of these two Societies, so many of whom have had larger experience and achieved riper judgment than I have.

There can be no question of the duty of the state to care for its wards in accordance with the best judgment of the time, and to keep pace with the progress which a better knowledge is making for their protection, relief, or, if possible, cure.

Following, as we so closely do in many other things, the English law and practice, it has come to be an accepted fact that those who, from birth or by reason of the accidents and ills of life, are *non compos mentis*, are peculiarly deserving of the watchful guardianship of the state. The earliest English laws had only to do with the estates of these unfortunates, which were the king's prerogative, and out of which their owners were, by legal provision, provided for in accordance with the customs of the time. It came to be observed in time that enactments which had regard only to the estates of the insane did not meet all the requirements of the case, and that the persons as well as the estates needed care and custody. Having in view always the "liberty of the subject," which could not be violated without due process of law and for good and sufficient reason, statutes were framed which permitted the restraint of the insane, confining the application at first to those only who were manifestly dangerous to themselves or to others. Gradually the ques-

p. 273



tion of confinement for curative purposes came to be considered, and its necessity admitted, until at the present time all civilized countries recognize in some way the legality of commitments to asylums and hospitals of those of the insane who are not of necessity dangerous, but whose detention is justified by the exigencies of treatment.

It is the natural outgrowth of all theories of government which pretend to be paternal in form that the state should afford to its citizen protection, and particularly so "when he is without the use and enjoyment of his mental powers." The means to this end will always be a fair measure of the degree of advancement in civilization attained by the state.

In caring for her insane wards the state should seek those means which shall best accomplish—

1. The protection of the insane from themselves and from the cruelty and neglect of others.

2. The protection of its sane citizens from the violence of the insane.

3. The restoration of the insane to a condition of sanity.

I have placed these objects in the order in which they are usually enumerated, and in which the law usually regards them. In the order of their importance they should be reversed, for the restoration of the insane to a condition of sanity implies the accomplishment, in the course of its attempt, of all the others.

It is, I think, a fact which cannot be controverted that the insane are best cared for and their recovery most surely accomplished in organized hospitals devoted to their special treatment. This is certainly true of those of the indigent and pauper class, who cannot afford to make the arrangements which would otherwise be necessary, and I feel confident that the hospitals of the future will afford to all classes such accommodations that private care will be as unnecessary as it is often unwise.

To insure the proper treatment of its insane wards it becomes the duty of the state to make such provisions that all its insane can find ready and proper treatment in its hospitals.

In England and Wales the census of 1880 returns, on the 1st of January, 71,191 lunatics, idiots, and persons of unsound mind. Of these there were in county and borough asylums, hospitals, and district asylums, 44,035 paupers, 3513 private patients, and 655 criminals; in licensed houses, 1084 paupers, 3404 private patients, and 61 criminals; in workhouses (corresponding to our almshouses), 11,991 paupers; residing with relatives and others, 5980 paupers and 468 private patients.

It will be seen that of the 63,090 pauper insane, 45,219 (or nearly seventy-two per cent.) were in hospitals or licensed houses, and but 11,991 (or about seventeen per cent.) in the insane wards of workhouses, and these are, as required by the Commissions of Lunacy, only of the most quiet and harmless kind. Of the private insane, 7385 in all, all but 468 were in hospitals or licensed houses.

Let us compare this with the condition of the insane in the State of Pennsylvania, as shown by the United States census of the same year. Of the 8304 insane in this State, as enumerated in the census of 1880, but thirty-six per cent. were in organized hospitals, eighteen per cent. in almshouses, and forty-six per cent. at home. Massachusetts had sixty per cent. in hospitals, nine per cent. in almshouses, thirty-one per cent. at home; New York, fifty-seven per cent. in hospitals, eleven per cent. in almshouses, and thirty-two per cent. at home. Of all the large States, Pennsylvania had the smallest proportion of her insane in hospitals, and the largest in almshouses and at home.

Of all the insane in the United States in 1880, nine per cent. were resident in this State. Of all the insane in hospital but seven per cent. were in Pennsylvania, while sixteen per cent. of all those in almshouses were in Pennsylvania.

Here is a condition of affairs that may well attract attention. I am happy to say that since 1880 a larger number of insane have found accommodation in the hospitals and asylums of this State; but the number is still far below what it should be. According to the second annual report of the Committee on Lunacy of this State, its hospitals afforded accommodation for but 44.5 per cent. of the insane. As the hospital accommodations have not been increased, the percentage at this time is much smaller, owing to the natural increase and accumulation of chronic cases.

Having made suitable provision for the insane, the question of the legal admission and detention of this class is of next importance.

335

5003.
2381. Brains of Epileptics
132.
1.

Deposited by Dr. Dercum.

5014 Brains of the Insane.

From Norristown Asylum-

Deposited by Dr. F. X. Dercum.

5050 Brain of a Murderer
2384
132
1.

John Wilson, Hanged at Norristown

See Philadelphia Medical Times March 5, 1887.

Deposited by Dr. Dercum.

5121.00 Skin in cerebro-spinal meningitis.
Petechiae containing meningococci (type II).
Death from meningitis after days.
Pte. S.M. 42263. 2 Roy. Scot. Died 17/3/18.
Fulminating type. Subsidence of meningitis symptoms, then septicemia. At autopsy, acute vegetative meningococcic endocarditis on aortic and mitral valves.

Medical officer I. Roberts. Pathologist E. B. Krumbhaar.

Presented by U. S. Base Hospital No. 10.



5152 2. Tumor of Dura.
2387.
132
2.

5111. -- WOUND OF DURA MATER.
2382.
132.
1.

Pres. by Dr. T. Parrish.

5120. -- SUB-DURAL ABSCESS FROM CARIES OF THE MIDDLE EAR
2383
132
1.

Deposited by Dr. G. G. Davis.

5151. -- DURA MATER; OSSIFIC DEPOSIT.
2385
132.
2.

Presented by Dr. Mutter.

5152. -- DURA MATER: FIBROUS THICKENING.
2386.
132
2.

The dura mater shows at different situations a soft, shaggy, fibrous growth, only slightly elevated above the dura mater.

Presented by Dr. Mutter.

5160. -- ANEURISM OF ANOMALOUS VESSELS.
2390
132
2.

Dr. S. Weir Mitchell.

5177. -- BRAIN; HEMORRHAGE INTO RIGHT VENTRICLE.
2441
133.
6.

The hemorrhage was extensive; from a patient aet. 23 yrs.

From the Philadelphia Hospital.

5178.00 Dura Mater.

A small hole in the dura surrounded by yellowish granulation tissue. Thrombosis of longitudinal sinus. The adherent thrambus can be seen lying in the opened throbabus. (See specimen of skull cap No. 164)

Presented by U.S. Base Hospital No. 10.



(67)

5177.10 -- LEFT CEREBRAL HEMISPHERE; OLD CLOT IN THE CORPUS STRIATUM.

2388
132
2.

From a case of hemiplegia.

Presented by Dr. Wm. Pepper.

(5201) 5210-06

Hydrocephalic foetus.

2326
129
5

Parents natives of Denmark. Both apparently healthy. Married about one year.

Mother 36 years of age. First pregnancy. Breech presentation.

Delivery progressed normally until body had escaped. The skin was then noted to be macerated. (Movement had not been felt for several days.) Head remained transverse above the brim. Traction with finger in mouth had no effect. Forceps were of no avail. The hand was then introduced into the uterus and bimanual examination showed the head to be greatly enlarged. Being three or four miles from my of supplies, I punctured the occiput behind the pubes with household scissors rendered aseptic. This permitted the escape of a large quantity of fluid and the head was then readily delivered by traction. June 6th, 1894 recovery.

Presented by Dr. W.H. Morrison.

5178.00 Dura Mater.

A small hole in the dura surrounded by yellowish granulation tissue. Thrombosis of longitudinal sinus. The adherent thrambus can be seen lying in the opened throbabus.
(See specimen of skull cap No. 164)

Presented by U.S. Base Hospital No. 10.



(67)

5177.10 -- LEFT CEREBRAL HEMISPHERE; OLD CLOT IN THE CORPUS STRIATUM.

From a case of hemiplegia.

Presented by Dr. Wm. Pepper.

Hydrocephalic foetus.

(5201) 5210-06

Parents natives of Denmark. Both apparently healthy. Married about one year.

Mother 36 years of age. First pregnancy. Breech presentation.

Delivery progressed normally until body had escaped. The skin was then noted to be macerated. (Movement had not been felt for several days.) Head remained transverse above the brim. Traction with finger in mouth had no effect. Forceps were of no avail. The hand was then introduced into the uterus and bimanual examination showed the head to be greatly enlarged. Being three or four miles from my of supplies, I punctured the occiput behind the pubes with household scissors rendered aseptic. This permitted the escape of a large quantity of fluid and the head was then readily delivered by traction. June 6th, 1894 recovery.

Presented by Dr. W.H. Morrison.

5210 05 Tumor from the base of the brain.
2412
133
1.

5210 Tumor of the Brain.
2414
133
1.

Presented by Dr. Sinkler
See card & envelope
for description

2326
129
5

5210.16

5

cal attention. The principal trouble observed by the patient and his friends was the loss of eyesight, which had sunk to simple perception of light. During the day he sat about the house, and at night he was able, unaided, to go up three flights of stairs. In fact, a few days before his death, he dressed himself and came down stairs without assistance. There was no motor disturbance in any part of the body—no weakness of the muscles. Intelligence did not seem to be materially impaired. His memory for past events was retained. In illustration of this it may be stated that two weeks before his death he was visited by friends whom he had not seen for years, and conversed with them intelligently and rationally about events that had occurred ten years or more previously. For recent events, however, memory was defective. The drawling speech continued, and to this was added slight amnesic aphasia. Occasionally, he would be unable to remember a certain common word which he wished to use, but when it was suggested he would recognize it and be able to pronounce it without difficulty. Hearing was unaffected. The sense of smell was good, but whether or not there was any difference between the two sides could not be ascertained. The bowels and bladder acted normally.

I was called to see him at midnight on December 24, 1891, the statement being that he was in a stupor from which he could not be roused. When I reached the house, however, he was awake. He recognized me when I spoke to him, and his tongue was protruded normally. He lifted first one arm and then the other, and moved the legs at command. He had high fever, injected conjunctivæ, and other symptoms which caused me to believe that he was suffering from an attack of influenza, prevalent at that time. The following day his con-

*

281

...is in the newborn.
...d thirteen days.
...Dr Guy Hinsdale.

...ted by Dr Roberts.
...oma springing from the Sylvian
...h left facial paralysis, arm and
~~...logical Soc'y, 1887.~~

...Wharton Sinkler.

...S. Weir Mitchell

...orris Lewis.

...ted by Dr W.H. Morrison.

2415
133
2 Missing

5210.20 -- TUMOR OF THE BRAIN.

Three large sections 1/50 inch thick, showing tumor of the temporal lobe. It occupied the second and third temporal convolutions and encroached on the fourth.

History by Dr. H. C. Wood.

Mr. M. is a clergyman; two years ago he came under the care of Dr. S. Weir Mitchell for convulsive or epileptic attacks. In October, 1887, he became my patient; at that time he stated that in 1885 he began to have spells in which he would be

5210 05 X Tu
2412
133
1.
brain.

5210. X Tumo
2414
133
1.



dition was about the same, but next day he passed into a comatose condition and died that evening.

With the assistance of my brother, Fred. S. Morrison, the autopsy was made fourteen hours after death, the examination being confined to the head. The body was that of a stout, well nourished man, with nothing abnormal on inspection. The scalp was fully one-half inch in thickness, there being a quarter-inch layer of fat. The bone was of normal thickness, and the dura but slightly adherent to its inner surface. The dura was found strongly adherent to the pia mater along each side of the longitudinal fissure, and a portion of it was removed with the brain. A large tumor was at once evident in the left frontal region. The brain and tumor were removed as carefully as possible. It was found that the tumor had eroded the left half of the cribriform plate of the ethmoid, so that there was a direct communication between the interior of the skull and the nasal cavity.

From the inner surface of the frontal bone, one inch to the left of the median line and one inch above the orbital plate, there sprang a conical projection of bone. This had a base one-half inch in diameter, and projected three-eighths of an inch above the surface of the bone. Corresponding with this exostosis, there was a depression in the dura mater and in the new-growth. Inspection of the external surface of the bone showed no depression and no evidence of injury.

Examination of the brain and tumor, after removal, showed that the growth had occupied the greater part of the left anterior fossa of the skull. The mass is irregularly pyramidal in shape, its base, corresponding with the left half of the frontal bone, being attached to the inner surface of the dura. The base of the growth measures two and one-half inches vertically by three and one-quarter inches

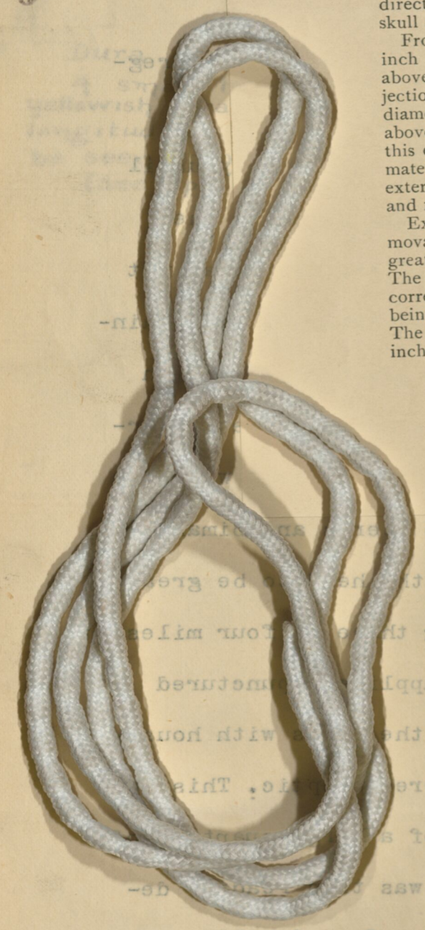

281

in the newborn.
thirteen days.
Guy Hinsdale.

ted by Dr Roberts.
oma springing from the Sylvian
th left facial paralysis, arm and
ological Soc'y, 1887.

Wharton Sinkler.

S. Weir Mitchell

Morris Lewis.

335

on-

wth

ulted by Dr W.H. Morrison.

2415
133
2 v missing

5210.20 -- TUMOR OF THE BRAIN.

Three large sections 1/50 inch thick, showing tumor of the temporal lobe. It occupied the second and third temporal convolutions and encroached on the fourth.

History by Dr. H. C. Wood.

Mr. M. is a clergyman; two years ago he came under the care of Dr. S. Weir Mitchell for convulsive or epileptic attacks. In October, 1887, he became my patient; at that time he stated that in 1885 he began to have spells in which he would be

5210 05 Su
2412
133
1.
brain
5210 Tumo
2414
133
1.



transversely. The tumor extends backward into the frontal lobes two and three-quarters inches. After preservation in alcohol for five months, the weight of the mass is five ounces, its volume nine cubic inches, and it displaces five fluidounces of water. The orbital plate of the frontal bone was not displaced, and there was no exophthalmus. The tumor was not adherent to the brain-tissue, but seems to be a dural tumor originating at the position of the projection of bone already mentioned, and thence extending gradually, pressing backward the frontal convolutions. Internally and externally the tumor was covered by cerebral tissue, but underneath, the brain-tissue has been displaced and absorbed in the position of the cribriform plate, and the bone itself has been destroyed. The tumor was readily lifted from its cavity, and, in fact, care was necessary to prevent it from falling out when the brain was removed.

The growth has been examined microscopically by Dr. C. W. Burr, who pronounces it to be a spindle-celled sarcoma.

The special features of this case, as elicited by post-mortem study, are: The evidences of a slowly-developing and steadily-progressing lesion, accompanied by pain in the head, not distinctly localized, not especially severe; a single epileptiform convulsion, neuro-retinitis, loss of memory, slowness of mental processes, slowness of speech, and slight amnesic aphasia. To these may be added absence of motor disturbances, and absence of signs of involvement of the special senses other than sight.

Referring to lesions in this region, Dr. Seguin says:[1]

[1] Pepper's System of Medicine, vol. v, p. 89.



5182 Suppurative Encephalitis in the newborn.
2389
132.
2. Portions of the brain of a child aged thirteen days.
Presented by Dr Guy Hinsdale.

2391
132
3. 5204 Spina Bifida. Sac excised. Presented by Dr Roberts.

5210.1 -- TUMOR OF THE BRAIN. Angeiosarcoma springing from the Sylvian
2413 fissure. Case of Miss S., aet 52. Showed slight left facial paralysis, arm and
133 leg normal. ~~Reported to the Phila. Neurological Soc'y, 1887.~~
1.
Phila. Med. Times 2/20/86 Presented by Dr. Wharton Sinkler.

Missing
5210.11 -- TUMOR OF THE BRAIN.
2416
133
2. Presented by Dr. S. Weir Mitchell
and Dr. Morris Lewis.

2417 5210.15 -- TUMOR OF THE BRAIN.
133
2 5210.16 " " " " Presented by Dr WH. Morrison.
2415
133
2 Missing
5210.20 -- TUMOR OF THE BRAIN.

Three large sections 1/50 inch thick, showing tumor of the temporal lobe. It occupied the second and third temporal convolutions and encroached on the fourth.

History by Dr. H. C. Wood.

Mr. M. is a clergyman; two years ago he came under the care of Dr. S. Weir Mitchell for convulsive or epileptic attacks. In October, 1887, he became my patient; at that time he stated that in 1885 he began to have spells in which he would be

5210 05 Lu
2412
133
1
brain.

P. 291 a

5210 Presented by Dr. Sinkler
Angeio sarcoma cerebri, 41 yrs
5210

MÜTTER MUSEUM.



5182
2389

Suppurative Encephalitis in the newborn.



lar or bipolar nerve-ganglia and the typical spider-cells with innumerable processes. Gliomata of this form are not uncommon. Klebs described fourteen or fifteen, and, of five cerebral tumors of the glioma-type which I have met with, only two were of the small-celled variety.

Dr. WHARTON SINKLER reported

A CASE OF BRAIN-TUMOR.

Miss S., æt. 52. Mother, maternal grandfather, great-grandfather, two maternal uncles, and two brothers died of phthisis. Paternal ancestors long-lived. No cancer. Healthy and well up to four years old. Then had a serious illness, spoken of by some as "brain fever;" another person says dysentery. Seemed to recover entirely from this, and was bright, well, and agreeable. Was not very intelligent mentally, but not by any means deficient. Catamenia first appeared at eighteen years. At seventeen years friends noticed a change in her: she was irritable, cross, and peculiar about many things. This condition of things continued through the remainder of her life, all the peculiarities becoming intensified. She was a great reader and a great eater. She was fond of literary pursuits, and spent a considerable amount of time in writing and painstaking composition. She never had convulsions, as far as known. At twenty-five years she was examined as to her mental condition by Dr. William Kirkbride, and he decided that, although not mentally vigorous, she was not insane.

For five or six years before her death, say forty-five years of age, she seemed to grow stouter, less inclined to work, and in walking seemed to move slowly and with difficulty. For three or four years before her death there was a drooping of the left corner of her mouth, most noticeable in smiling or speaking. This gradually increased. For eight or ten years she had had headaches.

In the summer of 1885 she was at Atlantic City, and had two or three attacks of violent headache associated with unconsciousness. These lasted several days at a time. She came under my charge in September, 1885. She then showed slight left facial paralysis, but no loss of power in arm or leg of either side. She complained sometimes of pain in the head, sometimes the shoulder or neck; seldom seemed to have persistent pain in one place. She had an attack of unconsciousness with severe headache; screamed with pain, but could check herself, and when asked what was the matter said she had pain, but could not state exactly where it was. At times she talked incoherently and spoke of having seen persons whom I knew she had never seen. She was unwilling to leave her bed, but, if she could be persuaded to get up, could walk about. Her appetite was good, but there were indigestion and constipation. No vomiting. Vision seemed good, but the

under the care of Dr. S. Weir Mitchell for convulsive or epileptic attacks. In October, 1887, he became my patient; at that time he stated that in 1885 he began to have spells in which he would be

Presented by Dr. W. H. Morrison.

recovery.

5210 05 Su
2412
133
1
brain.

281

Suppurative Encephalitis in the Newborn.

396 MEDICAL

eye-ground was not examined. She was eccentric in her way of talking, and said many things with the evident intention of creating surprise.

At my suggestion, she was taken to a country town in the vicinity of Philadelphia, and was there under the care of Dr. J. Reeve. After reaching this place, she complained of pain in the right side of the head and seemed unable to walk; would fall into a semi-unconscious condition, which would last for some hours. The temperature became elevated, the facial paralysis became [illegible], but, although no paralysis of the limbs, there was general muscular weakness. The patient died on October 26, 1885.

The post-mortem examination was made by Dr. H. Wharton. Upon exposing the membranes of the brain they were found markedly congested, and the dura mater was very adherent to the petrous portion of the temporal bone on the right side. Brain removed, membranes divided and turned aside. Upon left side there was no apparent lesion. On the right side some bulging of the membranes was apparent in the region of the fissure of Sylvius, and, upon dissecting them off, they were found very adherent to a tumor, larger than an English walnut, growing from the fissure of Sylvius about the line of the fissure of Rolando. The tumor was dead-red in color, stood out from the brain-tissue, and was dense to the touch. There was some effusion into the ventricles.

Dr. De Schweinitz made a microscopic examination of the growth, and sent me the following report: "The small portion sent for examination was hardened first in a solution composed of Müller's fluid one part, and methylic spirit three parts, for six weeks, and then in alcohol. Sections were cut, stained with carmine, and mounted in balsam. In the periphery the growth shows a structure composed of more or less perfectly developed fibrous tissue; more interiorly the stroma of the tumor is made up of numerous, variously-sized, dilated blood-vessels, sometimes empty, but for the most part filled with corpuscles. Between these are numerous small round and large spindle-cells (sarcoma-tissue) scattered through the growth, sometimes singly, often in groups; there are round, yellow [illegible] are probably [illegible] their nature. The tumor may be properly classed as an *angio-sarcoma*."

The growth, as may be seen, is spherical in shape, and springs up out of the fissure of Sylvius. The points of interest in the case to me are these. First, the probable long standing of the growth. It is likely that it began at the age of eighteen years, when mental peculiarities first showed themselves. Secondly, the absence of most of the symptoms peculiar to brain-tumor. There were no convulsions, no vomiting, no defects of vision, and no pain localized in one particular spot. The facial paralysis was not noticed until three or four years before death. There were many marked hysterical symptoms which masked the true nature of the disease. These, I think, are often met with in brain-tumors in women.

(To be continued.)

[illegible] Dr. S[illegible]itchell for convulsive or epileptic attacks. In October, 1887, he became my patient; at that time he stated that in 1885 he began to have spells in which he would be

Presented by Dr. W.H. Morrison.

Recovery.

giddy and lose himself for a minute. This continued until June 30, 1886, when unconsciousness lasted sufficiently long for him to fall. Similar attacks to this had occurred repeatedly before his visit to me, but in only two instances had there been violent convulsions, and there had been no history of headache or of any form of nocturnal attack. The attacks were not accompanied with aura or warning, except giddiness, which, he said, "seemed to deepen after a few seconds into unconsciousness." There was no cry, and no sleep after the attacks. The week before consulting me he had had three spells on as many successive days. His eyes were examined by Dr. de Schweinitz, who found choked discs and left lateral hemianopsia, and contracted field of vision.

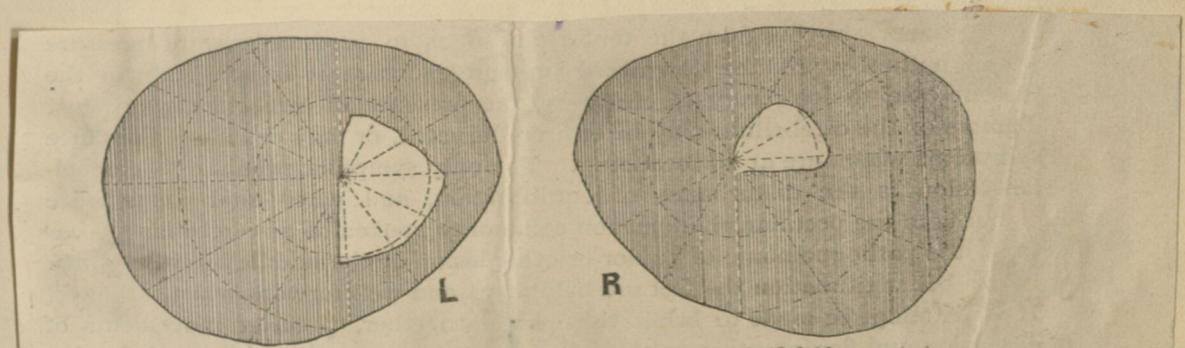


Left hemianopsia, with marked reduction of the remaining half fields, greatest upon the right side.

5215. A -- SARCOMA OF THE DURA MATER.

2392
132
3.

The tumor grew in the occipital region, softening the bone and projecting through the skull, forming a prominent tumor upon the occiput.

Presented.

5210.20 Continued.

On Saturday morning, February 9th, Dr. de Schweinitz found that *the vision had returned in the right eye*, and that the fields of vision were the same as when the hemiopic defect was originally found. (See Fig. 3.) Under all the circumstances, for the reasons which I stated in the last clinic, it was decided to operate on Mr. M. on Monday, February 11th.

Dr. Agnew opened the brain and exposed the cuneus, the region where I had located the tumor; this was apparently absolutely healthy. We felt of the brain cortex and of the tentorium, but there were no evidences of disease. When, however, the attempt was made to replace the brain into the dura mater,

FIG. 3.

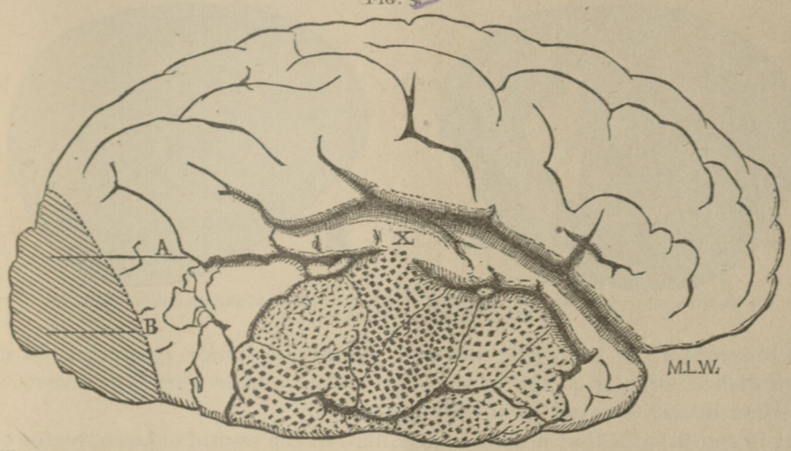


The dotted area represents the situation of the tumor. The lines A and B represent the position of softening running through the centre of the occipital lobe. The shaded area shows the portion of the brain exposed at the operation.

it was found impossible to put it back, showing that it was under great pressure. I then insisted on the cuneus being opened. When this was done, Dr. Agnew said at once, "There is a cystic tumor." The cavity was found immediately beneath the gray matter of the cuneus of a considerable size, and since the autopsy it has been determined that it is a patch of hemorrhagic inflammatory softening with definite walls formed by the infiltration of the brain substance by leucocytes.

Mr. M. lost a great deal of blood during the operation, and after a length of time it showed hardly upon him; but he rallied to a certain extent and regained consciousness, but two or three hours later commenced to fail in his circulation, and the same evening at 9 or 10 o'clock died.

When the autopsy was made, the brain, which is now before us, was removed. You see that there is occupying the second and third temporal and encroaching on the fourth convolution an enormous tumor, and, although we have cut down nearly two inches into the brain, still the tumor is perceptible. It occupies the centre of the lobe and reaches anteriorly and posteriorly through nearly the whole lobe. The uncinate convolution, the hook convolution, is not encroached or pressed upon. I want next to call your attention to the fact that there is a patch of hemorrhagic softening in the cuneus which is known as the region of visual perception; and that there is a line of softening running nearly the whole length of the centre of the occipital lobe. (See Fig. 3, lines B and A respectively.)

In cases of excessive choked disk, contraction of the field of vision occurs, and the ophthalmologists were inclined to believe that in the present case this contraction had occurred irregularly in such a way as to produce the fields of vision that I have represented to you. On the other hand, I myself was of the opinion that two factors entered into the formation of the visual field; that there was a centric hemianopsia coincident with an irregular contraction from choked disk. I did not, and do not, believe it possible that such fields of vision can be the result of generalized disease of the two nerves. The question is an important one, for in perhaps a majority of cases hemianopsia co-exists with some contraction of the field due to choked disk. If it be possible for optic neuritis to produce such a field of vision as that of the present case, I think the recognition of centric hemianopsia could rarely be a certain one. So far as this question is concerned, the autopsy shows that my opinion was correct, and that there was a lesion far back in the centres of visual perception.

5302. -- PORTION OF THE SPINAL CORD AND MENINGES;
2418
133
2. SOFTENING.

The white and gray matter of the cord has undergone a softening process for about 10 cm. The spinal nerves are seen emerging from their sheath at their proper intervals.

Presented by Dr. Mutter.

5305. -- PACHYMENINGITIS SPINAL CORD.
2443.
134.
1. Two specimens, presented by Dr. Jno. H. Musser.

5402. --
1665
51 Cast showing areas of anaesthesia and analgesia and impaired sense of touch; Jan. 27, 1879, seventeen weeks after accidental section of ulnar nerve.

Case of Theresa Heald, aet. 13.

5402.10 --
1666
51 Cast showing areas of anaesthesia, impaired sense of touch and pain on pinching skin and on pressure after section of the musculo-spiral and median nerves.

Case of Miss H. Totten.

5402.15 --
1667
57 Showing condition of anaesthesia, etc., after section of the median nerve.

See Trans.Coll.Phys.Phila., 1876, p.22.

Case of Bella Hutton.

5402.20 --
1668
57 Areas of Dysaesthesia, causalgia, etc., 2-21-82.

Case of Lydia Coles.

5402.21 --
1669
57 Areas of Dysaesthesia, 19 days after stretching median nerve.

5402.22 --
1670
57 Lines of Operation. Median stretched. Radial cut.

See Amer.Jour.Med.Sci., Jan. 1883.

5408. -- PORTION OF THE MEDIAN NERVE; NEURITIS FROM SPLINTERED BONE; FROM A CASE OF GUNSHOT WOUND.
2397
132.
3.

The bone was splintered longitudinally, and is attached firmly to the nerve sheath. Microscopic section gave evidence that this fragment of bone was in process of growth.

From J. G., a night watchman, shot with a

5411 Ligamentous Preparation of foot.
2837 Pres. by Mr. James K. Young.
134
6040 see Vol II Page 347
~~5411~~ 5 Amputation of Knee after excision
2844 Showing line of union.
132
3 Pres. by Mr. James K. Young.

(71)

pistol in the lower arm. He had profuse hemorrhage, false aneurism, membranes of the forearm and hand shortly after the accident, increasing pain. Suppurative inflammation pervaded the entire limb, and the pain was intense. Death occurred on the 49th day. The post mortem examination showed no tendency to repair but impending necrosis of the humerus.

Trans. Coll. Phys. Philada., May 3, 1876. 2:115

Presented by Dr. S. Weir Mitchell.

54

5410. -- HAND DISSECTED; FIBROUS TUMORS ON THE DIGITAL
2393 BRANCHES OF THE MEDIAN NERVE; THICKENING OF THE
132
3. MEDIAN AND ~~ULNAR~~ ulnar NERVE; EPILEPSY; AMPUTATION.

9

The muscles are atrophied and fatty degenerated. The median and ulnar nerves are hypertrophied one-third. On the second and third branches of the median nerve, are found two small tumors, each about the size of a coffee bean. The tumor on the second branch occupies a position opposite the articulation between the first and second phalanges of the thumb. That on the third branch is opposite the metacarpo phalangeal articulation of the index finger. The radial nerve is normal.

From a woman aet. 47 yrs. Since her seventh year she had epilepsy, the aura appearing in the thumb and index finger of the right hand, accompanied by involuntary contractions of these members, gradually

~~5500. Arthropathy. (Showing one of the joint's involved) 2~~
~~2395~~
~~132~~ ~~Pres. by Dr. H. C. Wood.~~
3.

5500.5 Arthropathy (Charcot).
2411 Pres. by Dr. H. C. Wood
133
1.

Tumors from sciatic nerve

passing to the head, terminating in convulsions. Amputation was adopted after all other treatment failed.

Presented by Dr. J. Ewing Mears.

X {Fibroma}
5410.01 Tumors from sciatic nerve & internal & external popliteal - about 3 dozen were removed from a man patient at the Methodist Hospital - By Dr. J. B. Roberts - Incision 18 inches long from gluteal muscle to lower end of popliteal space - Jan. 28th 1901.
Presented by Dr. John B. Roberts.

5500. --
2394
132
3.

Arthropathy (Charcot's disease).

Specimen of pied tabetique.

The specimens consist of portions of two feet.

The ankle joint exhibited no enlargement, nor did the articulating surfaces of the tibia and fibula yield any evidence of disease. The articulating surfaces of the astragalus, however, were here and there denuded of cartilage and much roughened. Similar changes, though slight, were noticed in the calcaneum, but it was in and about the joint formed by the internal cuneiform and first metatarsal bones that the greatest amount of change had occurred. The cartilage had entirely disappeared from its upper portion. Here the two bones had become firmly united. The microscope revealed a continuous osseous structure from one to the other. The lower portion of the joint, which was equivalent to about three-fourths of its entire area was filled by continuous adherent surfaces of cartilage, while here and there a narrow chink representing the original cavity of the joint, was

left. The bones appeared enlarged and distorted, and an examination of their internal structure showed that the cancellated tissue had been replaced here and there by small masses of dense ossific deposit.

The middle cuneiform and second metatarsal bones were partly crowded over the internal cuneiform and first metatarsal bones, and presented lesions similar to those first described. The heads of the two metatarsal bones had in one place become continuous and one section revealed an isthmus of bone uniting an angle of the internal cuneiform with the head of the second metatarsal.

The general impression given by the study of these lesions was that of a mass of bones, which, being at one time softened, had been mechanically distorted and displaced. The absorption or deposition of bony tissue seemed to follow no rule, nor did the destruction of the cartilage distinguish itself by any peculiarity other than that it seemed to precede the changes in the bones.

Presented by Dr. H. C. Wood.

left. The bones appeared enlarged and distorted, and an examination of their internal structure showed that the cancellated tissue had been replaced here and there by small masses of dense ossific deposit.

The middle cuneiform and second metatarsal bones were partly crowded over the internal cuneiform and first metatarsal bones, and presented lesions similar to those first described. The heads of the two metatarsal bones had in one place become continuous and one section revealed an isthmus of bone uniting an angle of the internal cuneiform with the head of the second metatarsal.

The general impression given by the study of these lesions was that of a mass of bones, which, being at one time softened, had been mechanically distorted and displaced. The absorption or deposition of bony tissue seemed to follow no rule, nor did the destruction of the cartilage distinguish itself by any peculiarity other than that it seemed to precede the changes in the bones.

Presented by Dr. H. C. Wood.

## SPECIAL SENSES.

missing

5600. -- POST-OCULAR TUMOR OF THE LEFT ORBIT.

The specimen was removed from a person who had been blind for ten years. One year previous to its removal the tumor developed very rapidly for a few days; this was followed by no change. Before operation the eye was in a state of extreme exophthalmos with redness and pain.

Presented by Dr. C. Hermon Thomas.

DURA MATER; WOUND.

Presented by Dr. Isaac Parrish.

5610. -- STAPHYLOMA OF THE CORNEA.

2396
132
3

Presented by Dr. C. A. Oliver.

GENERAL PATHOLOGY.

6000



t fron-

growth

nted

dinal

tual

m ap-

cond

D.

gth is

abruptly

Atlee.

el 70 yrs-

ophied,

6004. Ungual Exostosis from Big Toe.
2423.
133.
3. Pres. by Dr. G. G. Davis.

~~6005~~. ~~Elephantiasis of the leg~~

6002. Human horn (Model).

A large horn is seen projecting downward from the left frontal region reaching below the level of the chin. The growth is 22 cm. long and 3 cm. in diameter. It is represented as of the color of deer horn, having the same longitudinal striations.

6002-10 Human Horn.
2419
133
3.

This specimen is twisted like a ram's horn. Its actual length is 20 cm., and its diameter 1-3 cm. It is firm apparently very tough, and of a brown color.

From a woman aged 70 years. This was a second growth and was of seven years duration.

Presented by S.Beaus, M.D.

6002-20 Human horn. Missing
2420
133
3.

This specimen is similar to the last. Its full length is 13 cm., and its diameter at the base, 1-3 cm. It is abruptly curved at the distal end.

Presented.

Missing

6003. Hypertrophied toe-nails. Presented by Dr. W. F. Allee.
2421
133
3.

Eight fragments varying from one to 5 cm. in length and about 1.5 cm thick Removed from the feet of a patient aet 70 yrs-

6004 Ungual Exostosis from the Big Toe. Presented by Dr. G. G. Davis.
2422
133
3.

6005 Elephantiasis Graecorum; foot.
2424
133
3

The soft tissues of the foot are enormously hypertrophied,

1126.17
~~6006.01~~ → Humerus, Radius & ulna, showing hypertrophy associated with osteo-porosis

1126.18 ~~6006.02~~ → ~~Fibula Radius~~ Fibula etc

1126.19 ~~6006.03~~ → Section of left humerus etc

1126.20 ~~6006.04~~ → Humeri etc.

1126.21 ~~6006.05~~ → Rt. Femur.

1126.22 ~~6006.06~~ → Rt. Tibia, Fibula & Patella etc.

1126.23 ~~6006.07~~ → Rt. Ilium etc

1126.24 ~~6006.08~~ → Left. Ilium etc

1126.25 ~~6006.09~~ → Tibia

1126.26 ~~6006.10~~ → Vertebral column

1126.27 ~~6006.11~~ → Scapulae

1126.28 ~~6006.12~~ → Phalanges.

1126.29 ~~6006.13~~ → Left. Femur.

1126.30 ~~6006.14~~ → Clavicles.

1126.31 ~~6006.15~~ → Radius etc

Numbers on these specimens were changed 12/12/39 as the 6006.01-6006.15 series indicated Hypertrophy of Soft tissue. The series 1126.17 - 1126.31 indicates hyperostosis or hypertrophy of bone which is the correct way in which these specimens should be labeled.



presenting an irregular, warty appearance. The toes are thickened and distorted.

From the West Indies.

Presented by Dr. Ducachet.

6006.

~~6006~~

~~6006.01 to 6006.15~~

1126.17 to 1126.31 Specimens of this case.

1126.17
6006.01 — Humerus, Radius & ulna, showing hypertrophy associated with osteo-porosis

954
27
2.
1126.18
6006.02 — ~~Fibula Radius~~ Fibula etc

954
27
1
1126.19
6006.03 — Section of left humerus. etc

956
27
2
1126.20
6006.04
1126.21
6006.05
1126.22
6006.06
1126.23
6006.07
1126.24
6006.08
1126.25
6006.09
1126.26
6006.10
1126.27
6006.11
1126.28
6006.12
1126.29
6006.13
1126.30
6006.14
1126.
6006.

H. Faber del. et sculpsit.



presenting an irregular, warty appearance. The toes are thickened and distorted.

From the West Indies.

Presented by Dr. Ducachet.

1126.17 ✓
6006.01 — Humerus, Radius & ulna, showing hyperostosis associated with osteo-porosis
954 27 2.
1126.18 ✓
6006.02 — Fibula ~~Fibula~~ ~~Radius~~ etc
958 27 2
1126.19 ✓
6006.03 — Section ... etc
956 27 2
1126.20 ✓
6006.04 — Ulna
957 27 2
1126.21 ✓
6006.05 — Rt. Fe
958 27 2
1126.22 ✓
6006.06 — Rt. T
959 27 2.
1126.23 ✓
6006.07 — Rt. I
960 27 2.
1126.24 ✓
6006.08 — Left
961 27 2
1126.25 ✓
6006.09 — Ti
962 27 2
1126.26 ✓
6006.10 — V
963 27 2
1126.27 ✓
6006.11 — 964 27 2.
1126.28 ✓
6006.12 — 965 27 2.
1126.29 ✓
6006.13 — 966 27 2
1126.30 ✓
6006.14 — 967 27 2
1126.31 ✓
6006.15 — 968 27 2



presenting an irregular, warty appearance. The toes are thickened and distorted.

From the West Indies.

Presented by Dr. Ducachet.

## EXPLANATION OF PLATES I. AND II.

Fig. 1. Posterior surface of right Humerus.
" 2. Anterior surface of left Humerus.
" 3. Section of left Humerus.
" 4. " " natural size.
" 5. Section of left Femur.
" 6. Anterior surface of right Femur.
" 7. Posterior surface of right Femur. The notch about the middle is where a slice was removed for microscopic preparations.
Fig. 8. Section of left Radius.
" 9. Posterior surface of left Radius.
" 10. Posterior surface of right Radius.
" 11. Anterior surface of right Radius.
" 12. Section of left Ilium.
" 13. End of right Clavicle.
" 14. Posterior surface of right Ulna.
" 15. Anterior surface of right Ulna.
" 16. Section of left Ulna.
" 17. " " natural size.
" 18. Posterior surface of right Fibula.
" 19. Posterior surface of left Tibia.
" 20. Anterior surface of right Tibia.
" 21. Section of Phalanx natural size.
" 22. Section of healthy Phalanx natural size inserted for comparison.
Fig. 23. Vertebral end of spine of left Scapula.
" 24. Anterior surface of carpal end of right Radius enlarged.

N. B. All the drawings except where noted are on a scale of ½ the natural size.

1126.17 ✓
6006.01 — Humerus, Radius & ulna, showing hyperostosis associated with osteo-porosis
954 27 2.
1126.18 ✓
6006.02 — Fibula ~~Fibula~~ ~~Radius~~ etc
958 27 2
1126.19 ✓
6006.03 — Section ... etc
956 27 2
1126.20 ✓
6006.04 — Ulna
957 27 2
1126.21 ✓
6006.05 — Rt. Fe
958 27 2
1126.22 ✓
6006.06 — Rt. T
959 27 2.
1126.23 ✓
6006.07 — Rt. I
960 27 2.
1126.24 ✓
6006.08 — Left
961 27 2
1126.25 ✓
6006.09 — Ti
962 27 2
1126.26 ✓
6006.10 — V
963 27 2
1126.27 ✓
6006.11 — 964 27 2
1126.28 ✓
6006.12 — 965 27 2.
1126.29 ✓
6006.13 — 966 27 2
1126.30 ✓
6006.14 — 967 27 2
1126.31 ✓
6006.15 — 968 27 2



presenting an irregular, warty appearance. The toes are thickened and distorted.

From the West Indies.

Presented by Dr. Ducachet.

~~A CASE~~

OF UNIVERSAL HYPEROSTOSIS, ASSOCIATED WITH OSTEO-POROSIS, ~~WITH A DESCRIPTION OF THE SPECIMENS, by J. EWING MEARS, M. D., W. W. KEEN, M. D., HARRISON ALLEN, M. D., and WILLIAM PEPPER, M. D.~~

(*Extracted from Proceedings of the American Philosophical Society, Dec. 2, 1870.*)

The undersigned, to whom were referred the above specimens, presented by a friend to Dr. J. Ewing Mears, have carefully examined them, and have prepared the following Report:—

In the investigation of the subject, we have prepared as full a history of the case as could be obtained, a detailed account of the general anatomical characters of the disease, and of the peculiarities of each individual bone, as well as of the microscopic appearances, have consulted the works and periodicals in various languages accessible in this city, and have examined all the specimens contained in the Museums of the College of Physicians, Academy of Natural Sciences, University of Pennsylvania, Jefferson Medical College, and also the hospital and private collections in the city.

We have nowhere found specimens of this disease, or descriptions of such, at all equalling in extent and severity these here described.

The only similar case, though far less in degree and extent (skeleton imperfect), is found in Virchow's Archives, Vol. 43, 1868, p. 470, plate No. 12, although we have met with specimens and descriptions of skulls and bones which afford evidences of a limited development of the same disease.

Of the pathology of the disease, as well as of the anatomical appearances (116), we have found the best descriptions in Lobstein, Traité d'anatomie pathologique, Tom. II, p. 116; Boyer, Sur les Maladies, Chirurgicales, Tom. III, p. 571; Paget, Surg. Path. Eng. Ed., pp. 301–2, and fig. 40; Stanley on the Bones; S. Solly, Med.-Chir. Trans., Vol. 27; Förster Handbuch der Path. Anat., Bd. I, S. 249–52, and Bd. II, S. 850–4; R. Volkmann, in Pitha und Billroth's Handb. der Chirurgie, Bd. II, S. 249–58; Oeffinger, Virchow's Archiv, Bd. 43, S. 470; Haubner, Canstatt's Jahresbericht, 1854, Bd. 27, S. 23–4; Virchow, Die Krankhaften Geschwülste, Bd. II, Vorlesung XVII.

## HISTORY OF THE CASE.

Fully recognizing the importance the history of the case has in the discussion of the Etiology and Pathology of the disease, we regret our inability to add any information to the statement given at the time of the presentation of the specimens, which is as follows:—

A. M. aet, 14, native of England—occupation farm boy—came from England to this country when very young—father died in November, 1862, of Phthisis, aged 57—mother died in 1867, cause of death not ascertained—has one brother and one sister, both young and healthy. In September, 1866, while engaged at work on the farm, noticed swelling

1126.17 ✓
6006.01 — Humerus, Radius & ulna, showing hyperostosis associated with osteo-porosis
954 27 2.
1126.18 ✓
6006.02 — Fibula ~~Fibula~~ ~~Radius~~ etc
958 27 2
1126.19 ✓
6006.03 — Section ... etc
956 27 2
1126.20 ✓
6006.04 — Ulna
957 27 2
1126.21 ✓
6006.05 — Rt. F
27 2
1126.22 ✓
6006.06 — Rt. T
959 27 2.
1126.23 ✓
6006.07 — Rt. I
960 27 2.
1126.24 ✓
6006.08 — Left
961 27 2
1126.25 ✓
6006.09 — T
962 27 2
1126.26 ✓
6006.10 — V
963 27 2
1126.27 ✓
6006.11 — 964 27 2.
1126.28 ✓
6006.12 — 965 27 2.
1126.29 ✓
6006.13 — 966 27 2
1126.30 ✓
6006.14 — 967 27 2
1126.31 ✓
6006.15 — 968 2



beginning in the face, and also, that in stooping, face felt puckered and wrinkled, while the effort to regain the erect position gave intense pain along the entire spinal column. Subsequently the fore-arms became sore and swollen, was placed under treatment, which was of such decided benefit that he thought himself entirely well, and in March, 1867, resumed his farm duties; about two months later the symptoms returned in an aggravated degree, the feet and then, in succession, the legs and thighs becoming enlarged and very painful; under the influence of constant bandaging the swelling diminished; his appetite became impaired, and he died from exhaustion Feb'y 8th, 1868. The treatment adopted was mostly of a tonic character.

## DESCRIPTION OF THE SPECIMEN

(See Plates I. and II.)

### I. WHAT BONES ARE WANTING.

There is present ~~We have~~ the entire skeleton except the following bones:

Vertebræ—5th and 7th cervical.
1st and 10th dorsal.
2d lumbar.
2d and 4th sacral.
all the coceygeal.
Sternum, gladiolus and ensiform.
Hyoid bone.
Right Patella.
Hands, all wanting save the right scaphoid.
Feet, all wanting save left calcis.

Five metacarpal and metatarsal bones and eight phalanges are preserved, but, except the two metatarsals of the great toe, they can scarcely be designated, they are so greatly deformed.

### II. THEIR CONDITION.

Unfortunately, by the prolonged boiling to which they were subjected ~~before coming into our possession~~, the bones have lost probably all their animal matter, and are now almost as friable as if they had been burned. By removing the marrow, also, this has rendered the pathology of the disease much less clear and the microscopic examination much less valuable than it would otherwise have been. Moreover, it has removed probably all the gelatine, so that the chemical examination and the specific gravity would be worthless. Even the weights are, by reason of this misfortune, only of slight value. All the epiphyses too, except the coracoid process of the scapula, are separated from the shafts or bodies, and in some bones even integral parts are separated, *e. g.* the sacrum is divided into its component vertebræ and the innominate bone into two pieces. Many of the epiphyses are preserved, as will be indicated in describing each bone. The epiphyses have attached to them in many places the dried gelatinous articular cartilages of a transparent



brown color, and when an epiphysis has been incompletely ossified, the cartilaginous portion presents itself as a similar dried gelatinous mass. The ends of the shafts of the long bones are very ragged also, the cancellated substance being exposed and more or less broken.

### III. WEIGHTS AND MEASUREMENTS.

In order to have some relative standard of weight, we have also weighed the bones of a girl of about seventeen. But, it must be observed, that all these but the scapula (which wanted the acromion epiphysis) were weighed with all the epiphyses. These healthy bones were rather slender, but were also longer than the diseased bones (the diseased and healthy femurs being 14½ and 16 inches respectively, excluding the lower epiphyses).

| | *Diseased Bones.* | | *Healthy Bones.* |
|---|---|---|---|
| Femur (without lower epiphysis) | 8 oz. | Do (with all epiphyses) | 8 oz. 3½ drms. |
| Tibia ( " " " ) | 5½ " | Do " " | 5 " 1½ " |
| Humerus (with all epiphyses) | 3½ " | Do " " | 2 " 3½ " |
| Radius (without epiphyses) | 1½ " | Do " " | 6 " |
| Ulna (without lower epiphysis) | 2 " | Do " " | 6½ " |
| Clavicle ( " inner " ) | ½ " | | |
| Scapula ( " all epiphyses except coracoid) | 1 " | | |
| Fibula (without both epiphyses) | 1½ " | Do " " | 7½ " |

The following are the measurements in circumference of the bones, the same healthy skeleton as before being used for comparison.

| | *Diseased Bones.* | *Healthy Bones.* |
|---|---|---|
| Femur (middle), | 5 in. | 2½ in. |
| Tibia " | 4¾ " | 2½ " |
| (at tubercle), | 5⅝ " | 4⅞ " |
| Humerus (middle), | 4¼ " | 2 " |
| (above condyles), | 5 " | 3¼ " |
| Radius (middle), | 3½ " | 1¼ " |
| (lower fourth), | 4¼ " | 1⅞ " |
| Ulna ( " and middle), | 3½ " | 1⅛ " |
| (just below corocoid), | 4⅛ " | 1⅝ " |
| Fibula (lower fourth), | 1¼ " | 1⅜ " |
| Clavicle (acromial extremity), | 3¼ " | 2⅜ " |

The following are the diameters. In general the original limits of the bone were pretty easily distinguished. The external line of demarcation in the femur and the posterior in the tibia are so indistinct that the diameters of the original bones are not wholly reliable. All the diameters are derived from longitudinal sections by a circular saw, and they are all at the middle unless otherwise stated.

339

presenting an irregular, warty appearance. The toes are thickened and distorted.

From the West Indies.

Presented by Dr. Ducachet.

1126.17 6006.01 → Humerus, Radius & ulna, showing hyperostosis associated with osteo-porosis

954 27 2.

1126.18 6006.02 → Fibula

955 27 2.

1126.19 6006.03 → Fibula Radius etc

956 27 2.

1126.20 6006.04 → Sections etc

957 27 2.

1126.21 6006.05 → Ulna

1126.22 6006.06 → Rt. F

958 27 2.

1126.23 6006.07 → Rt.

959 27 2.

1126.24 6006.08 → Rt.

960 27 2.

1126.25 6006.09 → left

961 27 2.

1126.26 6006.10 → Tib

962 27 2.

1126.27 6006.11 → V

963 27 2.

1126.28 6006.12 → 964 27 2.

1126.29 6006.13 → 965 27 2.

1126.30 6006.14 → 966 27 2.

1126.31 6006.15 → 967 27 2.

1126.32 6006.16 → 968 27 2.



| | *Original Bone.* | *Diseased Bone.* | *Addition by Disease.* |
|---|---|---|---|
| Femur, | 1 in. | 1½ in. | ½ in. |
| Tibia, | 1 " | 1 1/16 " | 1/16 " |
| Humerus, | ¾ " | 1 3/8 " | 5/8 " |
| Radius (middle), | 7/16 " | 1 1/16 " | 5/8 " |
| (upper third), | ½ " | ⅞ " | 3/8 " |
| (lower third), | ¾ " | 1¼ " | ½ " |
| Ulna (middle), | 7/16 " | 1 " | 9/16 " |
| (at coronoid), | 5/8 " | 1½ " | 5/8 " |
| (lower third), | 3/8 " | 1 " | 5/8 " |
| Metacarpal (great toe), | ½ " | 1 1/16 " | 9/16 " |
| Phalanx " | 7/16 " | 1 1/16 " | ¼ " |
| Clavicle, | ⅜ " | ¾ " | 3/8 " |
| Fibula (upper & lower thirds) | 1/16 " | ¾ " | 7/16 " |
| Ilium ( 1 in. above acetabulum), | 1/16 " | ⅞ " | 1/16 " |

## IV. General Description.

The bones which have suffered the most are the clavicle, humerus, radius, ulna, femur, tibia, fibula, metacarpals, or-tarsals and phalanges of both hand and foot. These are diseased in almost the entire length of their shafts. The radius and ulna have suffered rather more than any of the other bones just named. All the other bones of the trunk have suffered to some extent, those of the skull but very little or not at all.

Comparing the upper and the lower extremities, there is no appreciable difference in the violence of the disease.

Comparing the two sides externally, not only is there no difference in the extent and character of the disease, but there is the most remarkable symmetry of the corresponding, diseased bones, which may be traced even to details. (Figs. 9 and 10.) The disease begins and ends on both sides at corresponding points, it changes in character from simple porosity to the growth of osteophytes at corresponding points; if on one side the posterior part of the bone is most diseased, the same is true of the other side; if the osteophyte growth is continuous or interrupted on one bone (fibula Fig. 18) it is so on the opposite one; if one is unusually diseased at a tendinous or aponeurotic insertion, so is its mate; if a groove or a variation in color exist on the one side, the same will be found on the other side; even of single marked spiculæ of bone the same may be said; so that a description of one side will answer for both, minute differences being noted as they occur.

The main violence of the disease is expended on the shafts of the long bones. The epiphyses, of which the most important remain, *e. g.* those of the femur, tibia, humerus, &c., show we may almost say no disease. The lower epiphysis of the femur is slightly porous in the usually compact layer of the articular surface, but so fine is the porosity and so slight the disease that it would not be observed save on a most careful examination.



The other epiphyses show occasionally still slighter disease. Indeed it is a question whether this be not the result of the prolonged boiling. The bones of the trunk are but little affected except the sternum, which must have suffered severely, the manubrium being very porous and much thickened. The bones of the head are scarcely at all affected.

The point of greatest development of the disease varies with its character. 1°. The thickening is most developed in the middle of the shafts, and here generally the sclerosis is furthest advanced. (Figs. 3, 4, 5, 21.) 2°. The porosity is not noticeably greater in any particular parts of the shafts, but seems externally to be equally diffused. 3°. The osteophytes follow a marked law in their development. They are most developed where the muscles, aponeuroses, fasciae, &c., are attached, *e. g.* the linea aspera, interosseus ridges of the tibia and fibula, radius and ulna, the insertion of the deltoid, biceps and brachialis anticus, the condyloid ridges of the humerus. But it is not always true conversely, that where a large muscle is attached there must be a large osteophyte growth, *e. g.* there are none at the origins of the pectoralis major and sterno-mastoid, the supra- and infra-spinatus, the insertion of the quadratus femoris, &c. One class of exceptions is, however, to be noted, viz: that at the attachment of those muscles and ligaments that are connected to epiphyses, there is generally no disease, *e. g.* the muscular attachments to the greater and lesser trochanters, the greater and lesser tuberosities, tubercle of the tibia, the tuber ischii and nearly all the ligaments. The epiphyses and their attached parts are very nearly all quite free from disease, though it may be largely developed in their immediate neighborhood.

The direction of the nutritious artery seems to have had no influence on the development of the disease either in its extent or degree.

The porosity varies in its character, and usually any one bone will show all its varieties. 1°. The surface of the bone presents a very fine cribriform appearance, resembling pumice stone. When magnified six or eight times this is seen to consist of a stout network of bone perforated by numerous small foramina, which are generally tolerably circular, and do not communicate one with another. (Fig. 24.) 2°. It may be of a finer velvety appearance. This by the same power is seen to consist of the same network of bone, whose very large foramina or meshes now communicate and are therefore very irregular in form, while the ridges forming the bony net-work are very thin and form relatively high walls between the adjacent meshes. Sometimes these ridges assume a tolerably regular parallelism, giving a striated appearance to the part. 3°. A coarser appearance is often produced by a similar honey-combing with large foramina or meshes, deep and irregular, varying in size from a horse-hair to a line in diameter with the first or second variety existing in the intervening ridges. (See lower end of Humerus, Fig. 1.) 4°. The surface is often pierced more or less sparsely by small foramina about the size of a horse-hair. (Fig. 20.)

The osteophytes vary greatly also in their character. In shape they



presenting an irregular, warty appearance. The toes are thickened and distorted.

From the West Indies.

Presented by Dr. Ducachet.

1126.17 ✓
6006.01 — Humerus, Radius & ulna, showing hyperostosis associated with osteo-porosis
954 27 2.
1126.18 ✓
6006.02 — Fibula ~~Fibula~~ ~~Radius~~ etc
958 27 2
1126.19 ✓
6006.03 — Section ... etc
956 27 2
1126.20 ✓
6006.04 — Ulna
957 27 2
1126.21 ✓
6006.05 — Rt. F
958 27 2
1126.22 ✓
6006.06 — Rt.
959 27 2.
1126.23 ✓
6006.07 — Rt.
960 27 2.
1126.24 ✓
6006.08 — Left
961 27 2
1126.25 ✓
6006.09 — T
962 27 2
1126.26 ✓
6006.10 — V
963 27 2
1126.27 ✓
6006.11 — 964 27 2.
1126.28 ✓
6006.12 — 965 27 2.
1126.29 ✓
6006.13 — 966 27 2
1126.30 ✓
6006.14 — 967 27 2
1126.31 ✓
6006.15 — 968 2



are either pointed, flat, or clubbed, sessile or pedunculated. They frequently form larger or smaller scales, which cover more or less of the bone. They vary from the smallest size visible up to $\frac{3}{4}$ inch in length or $\frac{1}{2}$ inch square. They are often compound, smaller ones growing from larger ones as a base. Imbrication is not unusually a marked feature, and whether imbricated or not, their direction or "trend" almost always follows that of the fibres attached at that point. This is very marked where adjacent muscles run in different directions, *e. g.* the flexor attachments of the radius and ulna as contrasted with that of the pronater quadratus. (~~Figs. 11 and 15.~~) The grooves between the osteophytes have sometimes rolling edges, sometimes are as sharp as if cut with a knife, and often lie closely together and parallel; they are apparently made in many cases by the numerous small vessels. All of the osteophytes are more or less porous.

The color is usually normal, but in some places is of varying shades of brown.

On a section the whole bone is seen to be encased with a new formation of bone. This is true not only of the long bones but also of the scapulæ and ossa innominata. Viewing these bones and also many parts of the shafts of the long bones on the surface, one would suppose he had simply to do with the original thickened bone which had undergone this porous change. But a section shows that there is a complete new formation which is added layer after layer around the old bone. These layers (excepting where sclerosis has taken place) are separated by interspaces sometimes just appreciable to the eye, sometimes a quarter of an inch wide. (~~Fig. 17~~). The outer layer is often very thin, but presents to the eye that deceptive appearance of apparent compact tissue which has simply become porous. Where sclerosis has taken place or osteophytes are developed, of course the thickness of the outer layer is either greatly increased or else undeterminable. The other layers also vary in thickness from the development of the sclerosis from the thinnest possible to one or two lines. "These layers may sometimes be traced into continuity with those forming the healthy portion of the wall" * of the original bone, especially at the extremities of the shaft. (~~Fig. 4.~~) At these points, starting from the original compact tissue, the several layers of the encasing new formation gradually become more and more widely separated or new layers may appear, thus producing a very great thickening at the centre, while at the ends of the shaft the thickening gradually (sometimes suddenly) diminishes. The interspaces between the layers are sometimes for even an inch wholly void, but they are generally filled with intervening trabeculæ of bone, which form a cancellated tissue and also support the superimposed layer to which they are always *perpendicular*. To a very large extent these layers have been welded together by sclerosis, and sometimes the new growth and the original bone present no line of demarcation by which they can be distinguished. Where this solidification has taken place, the cut surface instead of the uniform ivory-like solidity of normal compact

* Paget. Surg. Path. Eng. Ed. 1863, p. 301-2, and fig. 40.



tissue presents a granular appearance, as if the cancelli of the interspaces were not solidly filled up. The process of sclerosis not infrequently dips down like a cone whose base is of considerable extent at the surface of the new growth and whose apex just touches, or is sometimes welded with the original compact tissue. (Fig. 21.) Eburnation has nowhere taken place.

The original bone, too, has undergone marked changes. Its limits are generally pretty well defined, but the compact tissue of which its wall once consisted, is now cancellated, to a greater or less degree (osteo-spongiosis). Sometimes all appearance of compact tissue, save a mere worm-eaten porous external film, has disappeared. Sometimes no cancellation appears, but the old and new growths are welded together. The cancelli of the once compact tissue of the old bone always run *parallel* with the *axis* of the bone, and are thus easily distinguished from those of the spaces between the laminæ of the new growth which run at *right angles* to the surface of the bone. (Figs. 4 and 17.) The old cancellated tissue has often very large cancelli and in some cases has disappeared, leaving a wider medullary canal than is normal.

The epiphyses do not appear materially altered on section.

V. Description of Individual Bones.

1. *Head.*—All the bones of the head are present, completely disarticulated. The spheno-occipital suture was not ossified. No sections were made of these bones, and the external appearances alone are described.

(a) Frontal. The roof of the orbit, especially in the fossæ for the lachrymal glands, is somewhat porous. Internally the porosity appears over various parts of the perpendicular portion. The irregular striated appearance from large numbers of fine grooves is marked, and sclerosis seems to have made considerable progress.

(b) Parietal. Externally slightly porous at the posterior border; internally also over, say one-fifth of the surface, corresponding to the protuberance.

(c) Occipital. Externally small scattered patches of porosity; internally the same change is limited to the superior fossæ and the groove for the left lateral sinus.

(d) Sphenoid. Porosity of external surface of greater wings, and also in most of the pterygoid plates, which are somewhat thickened.

(e) Temporal. Slightly porous and thickened externally on squamous portion, and in the glenoid cavity and in the grooves for both lateral sinuses.

(f) Sup. Max. Slightly porous on anterior surface, and at the tuberosity. The alveoli are reticulated so as to resemble almost the meshes of the pulmonary structure.

(g) Palate. Internally, slight porosity at the junction of the perpendicular and horizontal portions.

(h) Inf. Max. Ascending ramus markedly thickened, and porous internally and externally; most developed at the centre of the ramus;



presenting an irregular, warty appearance. The toes are thickened and distorted.

From the West Indies.

Presented by Dr. Ducachet.

1126.17 6006.01 — Humerus, Radius + ulna, showing hypertrophy associated with osteo-porosis

1126.18 6006.02 — Fibula, Radius etc

1126.19 6006.03 — Section

1126.20 6006.04 — Ulna

1126.21 6006.05 — Rt.

1126.22 6006.06 — Rt.

1126.23 6006.07 — Rt.

1126.24 6006.08 — Left

1126.25 6006.09 — T

1126.26 6006.10 — V

1126.27 6006.11 — 964 27 2

1126.28 6006.12 — 965 27 2.

1126.29 6006.13 — 966 27 2

1126.30 6006.14 — 967 27 2

1126.31 6006.15 — 968

presenting an irregular, warty appearance. The toes are thickened and distorted.

From the West Indies.

Presented by Dr. Ducachet.



body similarly affected, principally between the mental foramen and the external oblique line. Alveoli like those of the upper jaw. This bone has suffered more than any other bone of the skull.

*Condition of Teeth.*—The teeth were all present, and were carefully examined. They were very brittle, so as to break across with little difficulty (see *Micros. Ex.*), but presented no peculiarity of shape. The entire absence of the peculiar deformity of the incisors, noted by Hutchinson, of London, as characteristic of hereditary syphilis, is to be especially marked as it bears upon the question of causation of the morbid process.

2. *Vertebræ.*—The epiphysal plates of the bodies, and the epiphyses of the transverse and spinous processes, are all gone. In the dorsal region the groove between the three original parts in which the ossification takes place, is very deep, but they are all united more or less. This groove gradually disappears both above and below, none of the remaining cervical vertebræ showing it, while inferiorily it is visible as far as the first sacral. On section the body is not much thickened, and no line of demarcation exists. No sclerosis has taken place.

(a) Cervical. Scarcely noticeable porosity of the anterior surface of body. Posterior arch of atlas is unusually thick and dense.

(b) Dorsal. Marked porosity of external surface of body, which is elevated above the surface left by the removal of the slightly overlapping epiphysal plates, about one-half a line to a line. Spinous processes slightly porous.

(c) Lumbar and Sacral. Same as dorsal; the porosity of spinous processes being more marked.

3. *Sternum and Ribs.*—(a) The manubrium only is present, and is very thick and porous. No osteophytes.

(b) The ribs have lost all their epiphyses. They are not affected on the external surface, save slightly in one or two instances. On the pleural surface they are all porous, and often a little thickened. For about one inch from the head the entire bone is thickened and porous.

4. *Upper Extremities.*—(a) Clavicle. The sternal epiphysis is wanting. Where the surface for the articulation with the acromion should be, there is on each side an oval cup-like depression $\frac{1}{2} \times \frac{1}{4}$ in. and $\frac{1}{8}$ in. deep. (Fig. 13.) Its walls are perpendicular, its floor flat, and both are covered with a thin layer of compact tissue resembling that which covers all the ends of the diaphyses of the other bones next the epiphysal cartilage. It was filled, when first seen, with a small mass of dried tissue resembling the epiphysal cartilage already described. Possibly it may have been an unusual third centre of ossification for this bone. It was occupied, certainly, by some substance separate from the shaft of the clavicle, either a third centre of ossification, or a projecting piece of the acromion. If the former, it is a very unusual place for a supernumerary epiphysis.

The whole bone is thickened to about twice its normal width, and its surface is coarsely porous throughout. At the insertion of the ligaments on the under surface, the porosity is quite fine and velvety. At the inner half of the origin of the deltoid there are twelve to twenty stout and well



developed osteophytes. A few also exist at the middle of the insertion of the trapezius. The section shows the original bone distinct from the new growth at all points. The laminæ of the new growth are very distinct at most points. A large part of those of the under surface are more or less closely united by partial sclerosis. The original bony tissue is relatively but little altered.

(b) Scapula. The coracoid process is one-third united to the bone, but wants the epiphysis developed on it at about seventeen years of age. All the other epiphyses are absent.

The bone is porous throughout, save at the centre of the infra-spinous fossa; generally of the coarse variety, but very fine in certain spots. The whole bone is somewhat thickened, as can be seen without any section, at its posterior border and on the spine. (Fig. 23.) The latter being to a great extent denuded of the outermost compact, yet porous layer of the new growth, shows the reticulated trabeculæ which supported it, and through their meshes the old external compact layer of the original bone now all worm eaten and very thin. This is especially well seen at the two extremities of the spine. The axillary border of the bone is three or four times as thick as is normal, has a few coarse osteophytes, and a very deep and wide groove for the dorsalis scapulæ artery.

(c) Humerus. All the epiphyses are preserved except that of the internal condyle. The trochlear surface projects only to a level with the radial.

The whole shaft (Figs. 1 and 2) is involved in the disease, the least at the upper fourth, the other three-fourths being about alike. The porosity is almost wholly very fine or velvety. About two inches below the head, at the insertion of the Pect. maj., the anterior bicipital ridge is greatly thickened (especially on the right side). It is continuous with a very large elevated surface ($2 \times 1\frac{1}{2}$ in.) at the insertion of the deltoid. This is covered with a large mass of not very large porous osteophytes whose trend is generally upwards. One (r. side) or two (left) large flat imbricated osteophytes mark the posterior lip of the bicipital groove. At the musculo-spiral groove, which is well marked, the bone is finely porous, but presents no osteophytes. At the lower third, anteriorly, the bone presents numerous osteophytes, sometimes single, but generally in groups. They are sessile, porous, and in some cases imbricated; their trend is generally downwards, except just above the epiphysis, where they are at right angles to the bone. The two condyloid ridges, especially the inner, are greatly diseased. The external ridge (especially on the right side) has several large porous sessile outgrowths with intervening grooves, the largest groove about corresponding in position to the anastomotica magna artery. The internal ridge up to the insertion of the coraco-brachialis is covered with large knobby and porous, imbricated osteophytes, continuous with a similar remarkable growth on the posterior surface of the bone, covering the origin of the internal head of the triceps, which extends to the musculo-spiral groove above, and fades into simple porosity externally. At the origin of the external head of the triceps, there is also a

1126.17
6006.01 — Humerus, Radius & ulna, showing hypertrophy associated with osteo-porosis

954 27 2.

1126.18 — Fibula

6006.02 ~~Fibula Radius~~ etc

954 27 2.

1126.19 — Section

6006.03

956 27 2.

1126.20 — Ulna

6006.04

957 27 2.

1126.21 — Rt.

6006.05

958 27 2.

1126.22 — Rt.

6006.06

959 27 2.

1126.23 — Rt.

6006.07

960 27 2.

1126.24 — Rt.

6006.08

961 27 2.

1126.25 — Rt.

6006.09

962 27 2.

1126.26 — Rt.

6006.10

963 27 2.

1126.27 — Rt.

6006.11

964 27 2.

1126.28 — Rt.

6006.12

965 27 2.

1126.29 — Rt.

6006.13

966 27 2.

1126.30 — Rt.

6006.14

967 27 2.

1126.31 — Rt.

6006.15

968 27 2.

presenting an irregular, warty appearance. The toes are thickened and distorted.

From the West Indies.

Presented by Dr. Ducachet.



marked elevation covered with pointed osteophytes, and continuous with that of the deltoid insertion. The trend of all these osteophytes is downwards, and their color (especially on the right side) is a light brown.

The section (Figs. 3 and 4) shows the outline of the old bone obliterated in the lower third, and only faintly visible in the upper two-thirds anteriorly. In the posterior upper two-thirds the laminæ of the new growth are admirably shown, though even here the sclerosis is in some parts far advanced. The original compact wall in the superior one-third, anteriorily, and two-thirds posteriorly, has almost disappeared, the cancellation (spongiosis) is so great, and it is a typical illustration of this process in various stages. The original cancellated structure is either fragmentary, its cancelli being very large, or else it has entirely vanished, leaving an enlarged medullary canal.

(d) Radius (Figs. 9, 10 and 11.) All the epiphyses are gone, save the left upper one. Instead of being rounded externally, and showing a sharp interosseous ridge internally, it is almost cylindrical, increasing in diameter from above downwards. At the bicipital tubercle there is a crest of curved osteophytes under which, as in a cave, the tendon of the biceps was inserted. The oblique line is marked by a series of knobby, porous, slightly imbricated osteophytes, whose trend is downwards and inwards till they reach the insertion of the pronator teres, where their size increases, and their trend is upwards and outwards. The interosseous border is rounded off and marked by a series of deeply imbricated laminated osteophytes, all trending downwards, resembling a rounded surface deeply grooved by oblique parallel cuts of a thin saw. Where the pronater quadratus was attached, a large number of osteophytes exist in ridges, which run laterally. All the rest of the bone is thickened and porous, and where the muscles took origin, is covered with porous osteophytes.

In section (Fig. 8) the outlines of the original bone are visible throughout; the laminæ of the new growth are marked; the sclorosis is in various stages, and anteriorly for some two inches the new and old growths are almost welded together. The old compact tissue is wholly changed to spongy, and the medullary canal is increased in size.

(e) Ulna (Figs. 14 and 15.) The lower epiyhyses are absent. Like the radius, the ulna is involved in its whole length, and is about twice its normal diameter. At the insertion of the brachialis anticus, a cup-like depression surrounded by an elevated ridge of osteophytes, exists, somewhat similar to that on the bicipital tubercle of the radius. The anterior surface is covered with small porous osteophytes, with a slight downward imbrication. At the attachment of the pronater quadratus they become more marked in their development, and the imbrication is external. The interossecus ridge is rounded off and marked, as in the radius, but with several unusually large and deeply imbricated osteophytes with a deep groove, probably that of the interosseous artery. Externally a brown discoloration is seen, which is the most noticeable on the right side. Posteriorly the bone is coarsely



porous, but very few osteophytes exist, save on the lower third. The intervening grooves run transversely, but are neither deeply nor sharply cut.

On section (Figs. 16 and 17) the line of the original bone can be distinguished throughout; the laminæ of the new growth are very marked; the sclorosis has welded together all the new layers anteriorly, and at the junction of the upper and middle thirds, the new and old growths are almost melted together both anteriorly and posteriorly. The interspace between the old bone and the first new lamina reaches one-fourth of an inch in width just below the olecranum, and the distinction between the perpendicular trabeculæ filling it up, and the longitudinal cancelli of the once compact tissue of the old bone is very marked. The medullary canal is scarcely, if at all, enlarged, and, indeed, at the point of greatest sclerosis above named, the same process seems to have invaded the canal itself.

5. *Lower Extremities.*—(a) Innominate Bones. The ilium is separated from the ischium and pubes, which are firmly and indistinguishably united together at their rami, but at the acetabulum are distinct. The Y-shaped piece uniting them is preserved, and is loose on both sides. All the other epiphyses are missing. The bones are porous throughout but not to a marked degree. The thickening varies from $\frac{1}{4}$ to $\frac{3}{8}$ of an inch, being greatest just above the acetabulum. On the ischium and pubes no osteophytes exist, save one small lamina on the body of the right pubes. The ilium is free from them except above the acetabulum for a considerable space, on and around the reflected origin of the rectus, where large and strong osteophytes exist, with a trend inwards and upwards.

On section of the ilium, (Fig. 12) the external surfaces, which otherwise would be thought to be the porous surface of the original bone, are seen to be the outer layer of the new growth. The original compact tissue has undergone spongiosis to a great extent. Sclerosis is furthest advanced just above the acetabulum.

(b) Femur (Figs. 6 and 7). All the epiphyses are separated. Both heads and great trochanters and the left lower epiphysis are preserved. The latter shows some very slight porosity, as already noticed.

Anteriorly the inter-trochanteric line is marked by a well developed growth of short, thick, rather acuminate osteophytes, separated by grooves running in the axis of the neck. A similar line of more slender imbricated osteophytes runs parallel to the base of the great trochanter and trends toward it. These two lines form the letter A. Immediately within this letter A (especially on the left side) the trend of all the osteophytes turns sharply downwards and so continues to the lower $\frac{1}{4}$ of the bone, where they are perpendicular. They are not very marked in their development. Just above the end of the shaft, however, they form an overlapping sheath to the bone. In the middle of the right femur an aperture ($1\frac{1}{4} \times \frac{3}{8}$ inches) exists in the ensheating new growth, disclosing

1126.17 ✓ ~~6006.01~~ — Humerus, Radius & ulna, showing hyperostosis associated with osteo-porosis

954 27 2.

1126.18 ✓ ~~6006.02~~ — Fibula ~~Fibula~~ ~~Radius~~ etc

1126.19 ✓ ~~6006.03~~ — Section etc

956 27 2

1126.20 ✓ ~~6006.04~~ — Ulna

957 27 2

1126.21 ✓ ~~6006.05~~ — Rt.

1126.22 ✓ ~~6006.06~~ — Rt.

959 27 2.

1126.23 ✓ ~~6006.07~~ — Rt.

960 27 2.

1126.24 ✓ ~~6006.08~~ — Left

961 27 2

1126.25 ✓ ~~6006.09~~ — T

962 27 2

1126.26 ✓ ~~6006.10~~ — V

963 27 2

1126.27 ✓ ~~6006.11~~ — P

964 27 2.

1126.28 ✓ ~~6006.12~~ — P

965 27 2.

1126.29 ✓ ~~6006.13~~ — P

966 27 2

1126.30 ✓ ~~6006.14~~ — P

967 27 2

1126.31 ✓ ~~6006.15~~ — P

968 2



to view the original but altered bone. Posteriorly the osteophyte growth extends from half an inch below the lesser trochanter to within 2½ inches of the end of the shaft, and the same sheath-like appearance is very noticeable at its two extremities. Where not covered with osteophytes, the shaft is very finely porous and thickened. All the central two-thirds of the shaft is one vast mass of large, irregular, porous osteophytes. Their direction is not constant, but is in general downwards, and their shapes are very varied. The mass extends for about eight inches, along what was the tolerably sharp linea aspera, but is now about ¾ in. wide and about ⅜ inch thick. The posterior inter-trochanteric line and great trochanter are not affected, except a slight porosity in the former. The lesser trochanter is wanting, but for ½ in. around it there is no disease beyond some porosity save one squamous osteophyte on the right side.

On section (Fig. 5) in the axis of the head and great trochanter the outline of the old bone is not to be made out save internally, and then only imperfectly. The old and new growths are almost everywhere indistinguishably welded together. The laminæ of the new growth, too, are welded together save at a very few points. The old compact wall is still solid, but it looks granular and does not present the ivory-like solidity of normal compact tissue. The medullary canal is somewhat enlarged at the expense of its walls. At the lower extremity the trabeculæ of the cancellated substance are normal, but in the head and neck the arches for mechanical support are much less distinctly marked than is usual.

(c) Patella. The right patella is missing. The anterior surface of the left shows a few osteophytes trending downwards.

(d) Tibia. Both the upper epiphyses are preserved. The whole bone is greatly diseased and thickened to about twice its usual diameter. The tubercle is slightly thickened and presents a ragged edge above for articulation with the epiphyses, but the greater part of the tubercle being developed from the epiphyses the disease is not very marked. The crest is rounded in its whole length and porous. The internal sub-cutaneous surface presents marked swelling and porosity. There is but little osteophyte growth, and it is generally in the laminæ except at the sartorius insertion, where it is more developed. A number of deep grooves exist, generally longitudinal in their direction and most marked at the upper third. The posterior and external surfaces are covered with a warty growth of porous osteophytes which attain their greatest development at the interosseous border and especially at the oblique line. The general trend of all this growth is downwards. Grooves for the vessels are frequent and tolerably deep.

On section (antero-posterior) the outline of the old bone is distinct at the extremities, but in the central two-thirds it is barely visible in front and wholly lost behind, the sclerosis at this part having welded together all the laminæ of the new growth and the original bone. Even at the extremities the new laminæ are not very marked. The rarefaction of the original compact substance is of course therefore not marked. The medullary canal if at all altered is narrowed by the encroaching sclerosis.



(e) Fibula (Fig. 18). Its shaft alone is preserved, and its axis is slightly bent inwards. The whole bone is encased in a newly formed osseous growth which is sometimes simply porous, and is covered with sometimes an interrupted, sometimes a continuous, growth of warty osteophytes, all more or less porous. Posteriorly and internally this growth is most developed, the trend being downwards. The lower subcutaneous surface is greatly thickened and finely porous, but has no osteophytes.

On section the bone is doubled in its diameter, the outline of the original bone being only visible in about one-half of its extent, the sclerosis obscuring it at other points. The original compact tissue is rarefied by spongiosis, and the medullary canal is somewhat widened.

(f) Hand and Foot. They are considered together, as some of the bones are indistinguishable, and moreover, in general the same description applies to both.

(1.) Right scaphoid of hand. Not diseased.

(2.) Left calcis. Porous and enlarged throughout. Porous osteophytes are seen at the attachments of the tendinous sheaths internally, and one large flat one on the inferior surface. The epiphysis for the attachment of the tendo achillis is preserved, but shows no disease.

(3.) Metacarpus, metatarsus and phalanges. Two of the phalanges have their epiphyses attached but not united by ossification. The epiphyses are not diseased. No other epiphyses are preserved. All these bones suffer by far to the greatest extent in the centre, not at all at the head (viewed externally), and but little at the base, and the new growth is five or six times as thick on the dorsum as on the opposite surface. No osteophytes exist save on one of the metatarsal bones and at the ridges for the flexor sheaths of three of the phalanges.

On section (Fig. 21), compare also Fig. 22, the outlines of the old bones are very readily seen, the apex of the conical sclerosis having, at points, just touched the surface of the old bone. The original wall of compact tissue is wholly rarefied by spongiosis, and the cancelli of the new and old bone are readily distinguished by the different directions of their axes. The normal compact wall of the phalanges being very thick relatively, the changes in it are the more marked. Sclerosis has invaded from half to two-thirds of the new growth. The head of the bone is also markedly rarefied by spongiosis.

## MICROSCOPIC EXAMINATION.

The specimens from which the following description ~~and wood-cuts were made, were prepared with his well known skill by Dr. J. H. McQuillen. They~~ consisted of a transverse section through the thickened wall of a phalanx, embracing the thickness of the layers superimposed by the periosteum, but not of the entire original compact layer of the bone, and of a transverse section through the right canine tooth.

This

presenting an irregular, warty appearance. The toes are thickened and distorted.

From the West Indies.

Presented by Dr. Ducachet.

339

1126.17 ✓
~~6006.01~~ — Humerus, Radius & ulna, showing hyperostosis associated with osteo-porosis
954 27 2.
1126.18 ✓
~~6006.02~~ — ~~Fibula~~ Fibula ~~Radius~~ etc
955 27 2
1126.19 ✓
~~6006.03~~ — Section ... etc
956 27 2
1126.20 ✓
~~6006.04~~ 957 27 2 — Ulna
1126.21 ✓
~~6006.05~~ 958 27 2 — Rt.
1126.22 ✓
~~6006.06~~ 959 27 2 — Rt.
1126.23 ✓
~~6006.07~~ 960 27 2 — Rt.
1126.24 ✓
~~6006.08~~ 961 27 2 — Lef
1126.25 ✓
~~6006.09~~ 962 27 2 — T
1126.26 ✓
~~6006.10~~ 963 27 2 — V
1126.27 ✓
~~6006.11~~ 964 27 2
1126.28 ✓
~~6006.12~~ 965 27 2
1126.29 ✓
~~6006.13~~ 966 27 2
1126.30 ✓
~~6006.14~~ 967 27 2
1126.31 ✓
~~6006.15~~ 968 2



The section of the phalanx (Fig. A) exhibited a quite compact osseous structure—the Haversian canals being for the most part round, and rather small, though in some places they were irregularly shaped or oval, and larger. The intervening bone lamellæ were of unusual thickness,

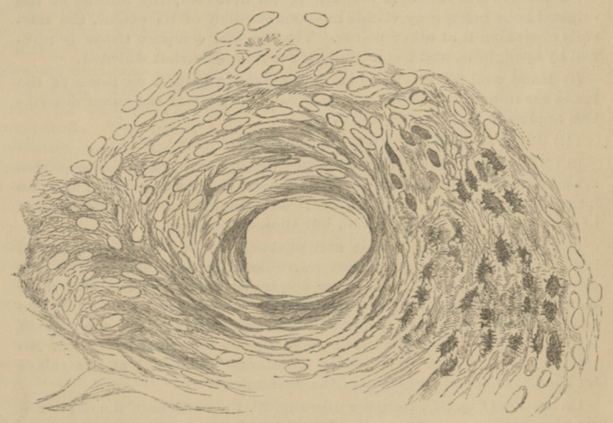

Fig. A.

and presented in the majority of cases, bone corpuscles with canaliculi. In some cases, however, no bone corpuscles were present, and the lamellæ appeared to be merely calcified by saturation with bone salts.

The bone corpuscles were small and often indistinct; in some places they were unusually round, but in others they presented the normal elongated shape; their canaliculi were invariably very poorly developed, and often could not be discovered.

With regard to the mode of arrangement of the bone lamellæ, they were always developed concentrically with (parallel to the walls of) the Haversian canals, and in no instance were any lamellæ found whose direction was parallel to the external surface of the shaft.



presenting an irregular, warty appearance. The toes are thickened and distorted.

From the West Indies.

Presented by Dr. Ducachet.



The section of the tooth (Fig. B) showed the existence of numerous irregularly shaped, branching lacunæ in the dentine near the marginal layer of enamel. These spaces were of various sizes and intercepted the

Fig. B.

course of a varying number of dental tubuli. They indicated unquestionably either an arrest of the process of calcification of the dentine, or of the resorption of calcareous matter already deposited, conditions which are also present in the true bony tissue. They are identical with the so-called *interglobular spaces* first described by Kölliker and carefully studied by Dr. McQuillen of this city, who has published (Dental Cosmos, N. S. Vol. VIII, No. 3, pg. 113,) several excellent illustrations of them.

## PATHOLOGY OF THE DISEASE.

Having thus described the gross and minute features of these bones, we would hazard the following remarks in regard to the nature and cause of the pathological process :—

In the first place it is to be observed that three separate processes, or at least three distinct stages of the same process, are represented in different parts of the skeleton, or even, in some instances, in single bones. These stages are :

We have, therefore first — First. Internal Osteoporosis of the original osseous tissue. 2d. External Hyperostosis, due to successive attacks of Periostitis, both of which processes are present in varying proportion in almost all the bones, and 3d. Secondary Induration.

Extracted from the Proceedings of the Amer. Philosophical Soc'y. Dec. 2nd 1870. (Read in 1870)
Vol. 12; pp. 19-36 - 1871 (printed in 1871)

1126.17
6006.01 → Humerus, Radius & ulna, showing hypertrophy
954 27 2. associated with osteo-porosis
1126.18 Fibula
6006.02 ~~Fibula~~ ~~Radius~~ etc
955 27 2
1126.19 etc
6006.03 Sectio
956 27 2
1126.20 Ulna
6006.04 957 27 2
1126.21 Rt.
6006.05 27 2
1126.22 Rt.
6006.06 959 27 2.
1126.23
6006.07 960 Rt.
27 2.
1126.24
6006.08 961 Left
27 2
1126.25
6006.09 962 T
27 2
1126.26
6006.10 963
27 2
1126.27
6006.11 964
27 2
1126.28
6006.12 965
27 2.
1126.29
6006.13 966
27 2.
1126.30
6006.14 967
27 2
1126.31
6006.15 968
27 2



1. It is especially in regard to the explanation of the internal osteoporosis, which constitutes so marked a feature of these specimens, that we regret the absence of any careful examination of the bones in their recent condition. In their present state, it is only possible to describe the degree to which this rarefaction of the osseous tissue has occurred, but it is evident that such changes might be produced by very varied alterations of the medulla and bone corpuscles. Thus, among the recognized causes of osteoporosis, may be mentioned syphilis, scrofula, rheumatism; and, in addition, we must add that both osteomalacia and simple ostitis produce changes in the bones which, after the specimen has been boiled, and the organic matter entirely removed, are not to be distingushed from the effects of the first mentioned diseases. In each case, under the action of the morbid irritant, whether purely external and local, or internal and constitutional, there is more or less rapid proliferation of the essential vital elements of the osseous tissue, called bone corpuscles or cells. At the same time, the bony laminæ surrounding the Haversian canals, and the walls of the lacunæ, are progressively deprived of their calcareous salts and removed, while the enlarged spaces thus produced are filled by the constantly growing cellular elements. The manner in which this removal of the calcareous salts is effected has been, and indeed remains, a subject of much discussion. The first idea which seems to have been entertained may be inferred from the name, eccentric atrophy, which was given to many specimens of osteoporosis, under the belief that the bony lamellæ were thinned and pushed asunder by the centrifugal pressure of the growing medulla. There is, however, no evidence whatever in favor of such a mechanical explanation, and this hypothesis has justly been almost universally abandoned.

By far the most plausible explanation which has been advanced appears to be that the removal of the calcareous salts, the first essential step in the destruction of the bony lamellæ, is due to the solvent action of some acid elaborated by the bone cells during the inflammatory process. According to Weber, their removal is not due to the direct action of any acid, but is owing to a gradual conversion of the insoluble *tri-basic* phosphate of lime into the more soluble *bi-basic* salt.

As this feature of rarefaction is, however, common to so many diseases of the bones, it is evident that the most characteristic results of such diseases are to be rather found in the condition of the bone cells, and in the characters of the morbid product which has resulted from their multiplication. And it is to be trusted, that by careful chemical and microscopical study of these, such peculiarities will be discovered as will enable us to distinguish with certainty in recent bones the various morbid changes.

Heretofore the majority of observers have limited themselves either to a description of the dried bone, after maceration or boiling, or at most, of the general characters of the medulla with which its cancelli are filled. And it results from this superficial mode of study, that there is as yet but



little exact knowledge of the really essential changes which the organic, active portions of bones undergo in disease.

Virchow, who was among the first to examine microscopically the condition of the bone cells in ostitis and some other diseases attended with rarefaction of the bone tissue, (Uber parenchymatöse Entzündung; Virchow's Archiv. Bd. IV. Hft. 2: 1852, b. s. 301 to 311,) formerly regarded the process as essentially a degenerative one, due to the fatty degeneration of the bone corpuscles and the subsequent softening and removal of the area depending on these cells. We have already, however, stated the view which appears most plausible in regard to the removal of the calcareous salts, and so far from fatty degeneration of the bone corpuscles being a constant feature in the different forms of osteoporosis, it would appear from the careful researches of Ranvier (Archives d' Anat. et Phys., Norm. et Path., No. 1, 1868, page 69), that this condition of the cells is altogether characteristic of caries and limited to that morbid process. On the other hand, there is every reason to presume that these cells are influenced by various morbid causes, (inflammation, syphilis, rheumatism, gout, scrofula, &c.) in the same way as the other tissues of the body, and give rise to products more or less characteristic of the diseased action present.

The history of the present case would appear to indicate that the nature of the disease was a rheumatic or scrofulous inflammation, but beyond this mere supposition we are prevented from advancing by the absence of any chemical and microscopical examination of the recent bones.

We would here again call attention to the marked peculiarity of the porotic bones, fully described at pages 24 and 25, and figs. 4 and 17, although we are unable to suggest any plausible explanation of the invariably parallel arrangement of the meshes of the porotic bone, and of the equally uniform vertical arrangement of the meshes of the new-formed sub-periosteal layers.

2. Another important appearance present in the bones here described, and indeed one which is as marked and wide-spread as the osteoporosis, is the extensive development of bone upon the exterior of the original shafts. In our description of the skeleton, we have already noted the peculiarities of these sub-periosteal growths, and it will be remembered that they are in every instance limited to the body or shaft of the bones, and never extend on to the epiphyses, and that they usually present several thin laminæ of imperfectly compact bone, parallel to the shaft and separated from it and from each other by more or less wide interspaces usually occupied by coarse cancellated tissue.

It is undoubtedly from the examination of such specimens as this that the mistaken idea arose that the lamellæ, of which the original compact shaft was formed, had been pushed asunder by the great enlargement of its cancelli. It will, however, be seen from our description that the ap-



presenting an irregular, warty appearance. The toes are thickened and distorted.

From the West Indies.

Presented by Dr. Ducachet.

1126.17 ✓
6006.01 — Humerus, Radius & ulna, showing hyperostosis associated with osteo-porosis
954 27 2.
1126.18 ✓
6006.02 — Fibula ~~Fibula~~ ~~Radius~~ etc
958 27 2
1126.19 ✓
6006.03 — Section ... etc
956 27 2
1126.20 ✓
6006.04 — Ulna
957 27 2
1126.21 ✓
6006.05 — Rt.
27 2
1126.22 ✓
6006.06 — Rt.
959 27 2.
1126.23 ✓
6006.07 — Rt.
960 27 2.
1126.24 ✓
6006.08 — Lef
961 27 2
1126.25 ✓
6006.09 — T
962 27 2
1126.26 ✓
6006.10 — V
963 27 2
1126.27 ✓
6006.11 — 964 27 2
1126.28 ✓
6006.12 — 965 27 2.
1126.29 ✓
6006.13 — 966 27 2
1126.30 ✓
6006.14 — 967 27 2
1126.31 ✓
6006.15 — 968 2



pearances contradict any such supposition, and clearly show that while in the cancellated and imperfectly compact tissue of the original shaft a process of rarefaction (osteoporosis) has been advancing by atrophy of the bony lamellæ, there has also been an active process of periostitis resulting in the formation of thick layers of new bone on the exterior.

Another means of distinguishing the line of demarcation between the original shafts and the new-formed layers, is the abrupt change in the direction of the cancelli already referred to.

It is evident, also, that the periostitis has not been uniformly continuous, but that for a variable time its intensity was such that the inflammatory product was capable of but imperfect ossification, and remained as cancellous tissue; while at irregular intervals thin layers of imperfectly compact tissue have been formed. The occurrence of this long standing, but not uniform process of periostitis ossificans appears to account, in every instance, for the changes observed on the exterior of the original shafts. In addition to this uniform hyperostosis, it will be observed from the description (see pp. 23, 24) that the same process of periostitis has given rise to varied forms of porous osteophytes.

3. In some places, however, it is evident that a still further change has occurred, consisting in the gradual conversion of the cancellous tissue into compact bone. This process of consecutive or secondary induration is most marked in the layers of bone formed by the periosteum; though it is present in the shafts of the tibiæ, femora and some other bones. It is manifestly impossible to determine accurately the portions which have been rendered compact by this process, but the disposition of the successive layers of new-formed bone is, in general, so much like that above described, that we are inclined to regard all the areas of compact bone of any considerable thickness as due to this secondary change.

It would, indeed, appear but probable that as the high degree of inflammation, under which the layer of cancellous tissue had been formed, subsided, there should be a tendency to the formation of successive layers of bone on the interior of the walls of the cancelli. It is especially in connection with this point that the result of the microscopical examination of the sub-periosteal layers is of so much interest. It will be observed (see Fig. A) that in the newly-formed compact bony tissue, the lamellæ are arranged concentrically around the vascular canals; a mode of arrangement which strongly points to the occurrence of the process of consecutive induration, as we have above described.

The specimens are deposited in the Museum of the College of Physicians.

J. EWING MEARS, M. D.
WM. W. KEEN, M. D.
HARRISON ALLEN, M. D.
WM. PEPPER, M. D.



presenting an irregular, warty appearance. The toes are thickened and distorted.

From the West Indies.

Presented by Dr. Ducachet.

~~6030. Calcareous degeneration of a fibroma~~

6030 10 - 6030.10 " " Choroid
2425
133
3.
Presented by Dr. C.A. Oliver

Gample with rubber tubing of approximation of intestine with Sims's decalcified bone plates.
Specimen of perforation of decalcified bone plates

414 Specimen with rubber tubing of modification of Roberts invagination suture.

416 Head, showing globule formed in urine, and wool sock stained by sulphide of lead.

6032, 1/ Experimental surgery on the intestine with reference to the healing of wounds, etc.
413
Sec 11
Shelf 2
Operations by N. Senn, M.D., of Milwaukee.

6032-1 Excision experiment,
404
Sec 11
Shelf 2
Six feet of small intestine excised. Union of divided ends by Czerny Lembert Suture, Killed; 161 days (dog).

6032-2 Gastro-entero-stomy. Apposition by decalcified bone
405
Sec 11
Shelf 2
plates, Killed in 34 days.

6032-3 Jejuno-ileostomy, Apposition by decalcified bone plates
406
Sec 11
Shelf 2
Killed in 23 days.

6032-4 Ileo-colostomy. Implantation by rubber ring method
407
Sec 11
Shelf 2
with omental flap, Killed in 23 days.

6032-5 Adhesion experiment, Gastro-enterostomy; by decalcified
408
Sec 11
Shelf 2
bone plates. Twenty-four hours.

6032-6 Adhesion experiment. Jejuno-ileostomy by decalcified
409
Sec 11
Shelf 2
bone plates- 6 hours.

6032.7 The same-12 hours.
6032.71
410
Sec 11
Shelf 2

6032-8 Adhesion experiment, Ileo-colostomy by decalcified
411
Sec 11
Shelf 2



6045.10 (1011) 1/ Flesh wound. Entrance and exit. .30 caliber, range 500 yrds.
6045.11 (1614) " " " " .45 " 500 grams " "
~~6045.12~~ " " " " .30 " range 500 yds.
~~6045.13~~ " " " " .45 " 500 grams " "

6045.12 Excised wound of scalp
Small wound of scalp, damaging outer table of skull. Excised and sutured. Later had to be reopened.
Death from diphtheria after 24 days.
Sgt. C.H.M. 24757. 12 K. Liv. Wounded 25/11/17. Multiple gunshot wounds. (See bone preparation No. 52. Part of skull).
Medical officer I. Roberts. Pathologist E.B. Krumbhaar.
Presented by U.S. Base Hospital No. 10.

6045.13 Skin wound.
The left and lower borders and the center of the upper border of the specimen are normal tissues. Its right border is mostly made up of the edge of the wound, which shows rounded edges with perforating epithelium and granulation tissues. The depth of the healing process is visible on the upper cut surface.
Arm amputated for gangrene following injury to brachial vessels.
Rfm. R.B. 1Btn. R.B. Amputation 24/11/17. Gunshot wound, fracture of humerus with pus in joint and muscle sheaths. Gangrene of hand.
Surgeon J.B. Flick. Pathologist E.B. Krumbhaar.
Presented by U.S. Base Hospital No. 10.

6045.14 Wound of skin and penis.
Surface of wound of left thigh necrotic with absence of healthy edge of epithelium. Note blebs on skin brownish lacerated wound. Small brownish lacerated wound of prepuse and laceration above the external meatus of the penis.
Death from gas bacillus septicemia after 23 days.
Pte. W.T.P. 3573. 1 New'fl'd Reg. Extensive skin wound remaining septic until gas infection supervened. Wounded 22/11/17.
Surgeon W.J. Taylor. Pathologist E.B. Krumbhaar.
Presented by U.S. Base Hospital No. 10.

bone plates- 48 hours.

6032-9 Enterorrhaphy. Rubber ring method with omental flap.
412
Killed after 44 days. The intestine is perfectly united.
Sec 11
Shelf 2

For a complete account of these experiments, see
Trans. Ninth International Congress,
Washington 1887.

~~6032.61~~
6040 see Vol II page 296.

6045. Wound of the Stomach. Case of Alfred Reed, 1-3-87 (Canor).
2426
133
3.

6095. Cellulitis of the hand and arm. Ankylosis of the elbow.
2353
130
5
Pres. by Dr. W.W. Keen.

Presented by Dr. W.W. Keen.

6095. Arthritis and cellulitis of the ankle-joint and foot.
10
2578
137.
6

Presented by Dr. Mütter.

X

6045.15 Skin wound of thigh.
The edge of the lower half of the wound shows healing (rounded and over hanging edge). The cross section (upper border) still shows some of the color changes of fas gangrene (hemorrhage and pallor). The tissue projecting from the cross section includes the femoral vein which at autopsy contained a septic thrombus.
Death from gas bacillus septicemia after 13 days.
Spr. S. 2595 Hsld. Btn. Wounded 12/10/17. Large wound of internal surface of left thigh. Treated with Eusol. Upper portion of wound remained edematous with pocket of pus running up thigh. Muscles gelatinous in appearance but no gas bubbles.

Surgeon W. Whittaker. Pathologist J. H. Cloud.
Presented by U.S. Base Hospital No. 10.

X

6045.20 Bladder.
Through and through wound. A window has been cut in the anterior wall between the wound of entrance and exit to exhibit the condition of the mucosa.
Death from acute cystitis and toxemia after 7 days.
Pte C. 11939 Wounded 28/11/17. (See Specimen of Pelvis).

Surgeon E.B. Hodge. Pathologist E.B. Krumbhaar.
Presented by U.S. Base Hospital No. 10.

X

6045.90 Spinal cord, vertebral column and rifle bullet.
Extensive laminectomy exposes spinal cord with adherent muscle. At the top and bottom of the specimen are normal dorsal spines and spinal cord with normal dura projecting Rifle bullet imbedded in vertebra with point flush with spinal canal. Note surrounding hemorrhage and necrosis.
Death from myelitis and septic pleurisy after 68 days.
Pte. C.C.M. 607.38 Btn. A.I.F. Wounded 5/10/17. Rifle bullet entered left shoulder fracturing rib and imbedded in vertebral column not found at operation.

Surgeon M. W. Vaux. Pathologist E.B. Krumbhaar.
Presented by U.S. Base Hospital No. 10.

6160.15 Missing Moist Gangrene of right arm
2843. following Hysterectomy.
132. Gangrene caused by Septic Embolus.
6. Pres. by Dr. W. J. Taylor. 1.1902.

41





6115. Arthritis of the knee-joint; "white swelling". The joint is
2540 is disorganized; the articular surfaces are roughened and
136 eroded and the surrounding tissues, swollen.
6.

Presented by ~~Dr. Mütter~~ Dr. Sinkler.

6150. Sloughing of the foot.
2427 The anterior portion of the foot, including the metatarsal
133 region, is in a state of slough. The bones are exposed to
3 full view. There is apparent laceration of tendon as though
caused by a crushing force.

Presented by Dr. Mütter.

6155. Caries of the thumb; amputated.
2428
133.
3.

Presented by Dr. Mütter.

6160 Missing Diabetic Gangrene of foot " " " O Hallis.

6160-10 Moist gangrene of the hand.
2444 The hand is that of a laborer. The dorsum is badly lacerated
134 and has sloughed about the wrist. The cuticle is partially
1. detached. The whole member is of a very dark color. The
radius and ulna have been sawn at the lower third.

Presented by Dr. Mütter.

6160-20 Moist gangrene of the foot.
2442 The lower portion of the leg and the ankle have been lacerated
133
6

Sloughing of the anterior aspect of the foot has occurred. The line of demarcation is well seen. The leg has been removed at the lower third.

Presented by Dr. Mütter.

6160-30 V
2445
134.
1.

Gangrene of the foot.

The entire metatarsal and digital regions ~~is in a state of~~ are gangrenous. The line of demarcation is very distinct. The heads of the metatarsal bones are very plainly visible. The tissues about the tarsal bones are shriveled.

Presented by Dr. Mütter.

6161. V
2446
134.
1.

Dry gangrene of the foot.

The foot has been removed at the ankle-joint. The tissues are firm, shriveled, and perfectly black.

Presented by Dr. Mütter.

6161.10 X

Part of foot.
Phalanges have already been removed for gangrene following trench foot. Note brown discoloration of exposed articular surfaces.
Amputated after 16 days.
Pte. A.S. 265361 Onset 15/1/18. Numbness of both feet on day after entering trenches. Pain next day. Feet swollen, pale, cold with black spot on little toe. Had been on active service 9 weeks. Feet normal before. Good results after two amputations.
Surgeon N. W. Vaux. Pathologist E. B. Krumbhaar.
Presented by U. S. Base Hospital No. 10.

6170. Sequestra of long bones.

Twenty specimens; the longest is 13 cm. long.

Presented by Dr. Mütter.

6170-05. Missing Sequestrum of a long bone.

2447
134.
1. Ten cm. long.

Presented by Dr. Mütter.

6175. Missing A portion of a long bone showing the process of necrosis.

Presented by Dr. Mütter.

6175.01 Missing Necrosis of a bone after amputation.

Presented by Dr. Mütter.

6170-10 Sequestrum from a long bone.

6175.02 Necrosis of a bone after amputation.

2448.
134.
1.

Presented by Dr. Mütter.

6175-05 Necrosis of humerus.

6170-15 Sequestra.

IX

6240.00 Descending Colon.

Large, irregular ulcers with rounded walls leaving tags and bridges of relatively normal mucosa. Although this has the appearance of amoebic dysentery, B. dysenteriae Shiga was isolated from the stool. Plastic peritonitis.

Death from dyentery after 2 months.

Driv. A.A.A. 25942 Army Transport. Date of onset 15/8/17. Had been in Egypt in 1916. Bloody and mucous diarrhoea, abdominal pain, loss of weight, fever, coated tongue. Toward the end bloody vomit and irregular pulse.

Medical officer W. Drayton, Pathologist Lieut. Cunningham.

Presented by U.S. Base Hospital No. 10.

6290.00

Intestine.

111 defined pale ulcers (longer in the transverse axis) with adhesions on peritonial surface. Tubercle bacilli were cultivated from the ulcers post mortem.

Death from tuberculous enteritis after 5 months.

P.O.W. W.B. 118 Company. Admitted to base 4/3/18. Diagnosis of Shiga dysentery. Diarrhoea only occasionally blood streaked. Stools negative. At autopsy chronic fibrous tuberculosis of pleura and lungs with caseation.

Medical officer J.M. Cruice. Pathologist E.B. Krumbhaar

Presented by U.S. Base Hospital No. 10.

## SARCOMATA.

6300. Lympho-Sarcoma. Primary tumor removed en masse. Extensive metastasis had already occurred.

6310. Alveolar Sarcoma of the Clavicle.

2398.
132.
4.

The tumor is of globular shape, having a diameter of about 6 cm. A portion of the clavicle is embraced in the specimen. The clavicle has softened and its continuity is broken.

From S. L. B., aet. 16 yrs. The growth was of five months duration. It was removed by Dr. John Ashhurst, Jr.,at the University Hospital. The patient recovered from the operation and went home in four weeks. In the course of three months, the disease recurred in the neighborhood of the cicatrix and she died.

Reported by Dr. G. E. deSchweinitz to the Philadelphia Pathological Society 12: 13, Jan. 8th, 1885.

Presented by Dr. John Ashhurst, Jr

6310-02 Sarcoma of the Scalp.

2399
132
4.

Presented by

Dr. P.S. Connor and

Dr. C.B. Nancrede.

6310-05 Spindle-celled sarcoma of the retro-peritoneum; extensive thrombotic degeneration.

2400
132
4.

The tumor occupied

a central position, was covered by peritoneum, and was attached to the tissues in front of the symphysis pubis and seemed to have grown from the sub peritoneal connective tissue in this region. The hand could be placed beneath it into the pelvis, and the whole mass could be lifted almost out of the abdominal cavity. There were a few slight adhesions to the sigmoid flexure and to a coil of small intestine. The upper part of the mass was represented by a soft fluctuating cyst, containing blood and shreds of firm thrombi; the greater part formed a solid mass, which in section presented a brownish red color; was firm, dry, and had all the appearance of an old, unstratified thrombus. In an area at least eight by seven inches in extent this remarkable condition existed. At the lower part, near the symphysis, there were two or three greyish-white masses, evidently of a sarcomatous nature, but the chief part of the tumor was composed of the blood cyst above and the large dry thrombus below. The capsule was formed of condensed fibrous tissue, beneath which in many places were recent extravasations. The weight was estimated as at least eight pounds. The lymphatic glands were not enlarged. The kidneys were fibroid and the ureters and pelves dilated from pressure. The liver presented several secondary masses, one the size of an orange. Nothing abnormal in the other organs Microscopical examination showed the primary and secondary masses to consist of closely packed spindle-cells.

From who the

a man aged 60, was admitted to University Hospital in September, 1884, with an abdominal tumor, which had been noticed for about six months. He had lost flesh and strength, but except a feeling of fulness after eating, there was no inconvenience. The tumor formed a solid mass, occupying a medium position, extending above the umbilicus and could be readily separated by palpation from spleen and liver. From the central position, slow and painless growth, and the absence of renal symptoms, the case was regarded as one of Lobstein's retro-peritoneal sarcoma. For several weeks the patient passed over seven pints of clear urine of low specific gravity, without sugar or albumen. The patient was subsequently admitted into St. Mary's Hospital under Dr. O'Hara, and while there, Dr. Mears aspirated the tumor.

Death took place April 1885.

Presented by Dr.Wm. Osler.

6310-10 Round celled sarcoma of the temporal bone.

2401
132
4

Presented.

6310-12 Sarcoma of the lachrymal gland.

2403
132
4.

Trans. Amer. Ophthal. Society 1882. Sec. 150-4 p. 3;407

Presented by Dr.Geo.C.Harlan.

6310-15 Round and spindle-celled sarcoma of the leg } 2466 134 6.

6310.16 Large " " " " . Thigh

2405
132
5.

Presented by Dr John Ashhurst.

6310.17 Sarcoma of the Uterus - Presented by Dr Jno. C. Da Costa. 1878.
2402
132
4.

6310.171 Sarcoma, fibroma and fibro Sarcoma in the same uterus - Presented by Dr J.C. Da Costa.
2432.
133
4.

6310-18 Sarcoma of forearm.

2408
132
6. A round celled sarcoma, Amputated in the arm.

Presented by Dr. J. Ewing Mears.

Presented by Dr.S.W.Gross.

6310.19 Large Spindle-cell Sarcoma of the breast.

2404.
132
4.

Presented by Dr John B. Roberts

6310-20 Large spindle-celled sarcoma of the thigh.

2410
132
6.

Removed from the posterior portion of the thigh of a patient in the University Hospital, under the care of Dr. Ashhurst. The patient was a man, thirty-two years old, who, some eight years ago, had first noticed a small tumor of the posterior portion of the left thigh, about six inches above the popliteal region. Since that time it had gradually increased in size, and at the time of his admission it was larger than a man's head and oblong in shape. Its growth had been accompanied by paroxysmal attacks of severe pain. The patient did not remember any injury of the part. The tumor was enucleated without difficulty, laying bare about six inches of the sciatic nerve, which was directly in contact with the capsule of the tumor, over which also portions of the semi-tendinosus and biceps muscles were stretched. The tumor was found to consist of one large cavity containing a reddish-brown fluid, surrounded by a fibrous wall varying in thickness from an inch to two inches, and in places presenting numerous points of calcareous degeneration. The inner surface of this wall was lined with irregular flocculent masses. Microscopical examination showed the growth to be a spindle-celled sarcoma with scattered areas of calcareous degeneration. The chief points of interest in the case were the large size of the tumor, its slow development, and the ease with which it was removed without injury to adjacent structures.

Missing

6310-21 Sarcoma of the thigh.

2429
133
4. Contains alarge calcareous plate.

Presented by Dr. S.R. Skillern.

6310-25 Osteo-sarcoma of the wrist.

2430
133
4. The disease has produced complete disintegration of the joint with great deformity.

Presented by Dr. Mütter.

6310-26 Osteo-sarcoma of the wrist.

2449.
134

Presented by Dr. Mütter.

4

6310-27 Osteo-sarcoma of the wrist.

2460.
134.
24 A large mass occupies the position of the wrist. On the radial side there is prominent growth as large as an orange.

Presented by Dr. Mütter.

4

6310-30 Osteo-sarcoma of the buttock.

2451.
134.
2

Presented by Dr. Mütter.

4

6310-31 Cystic-sarcoma of the buttock.

2452
134
2. Removed by amputation from a man aged 20 years. It occupied the left side, measured 80 cm. in circumference at the base and was one of one year's duration.

See Med.News, Philada. Nov. 8th. 1884 Philada. Acad. Surgery. 45: 522-523

Presented by Dr. J. Ewing Mears.

4

6310-35 "Fungous haematodes."

2431.
133
4.

Presented by Dr. Mütter.

4

6310-36 "Fungous haematodes" of the shoulder.

2406
132
5.

Presented by Dr. Mütter.

4

6310-40 "Osseous aneurism" (osteo-sarcoma) of the head of the tibia.

2440
133
6

The head of the tibia consists of an enormous cavity

partly enclosed by a thin shell of bone, with a comparatively smooth exterior and rough interior.

Presented by Dr. Mütter.

6310-41 Osteo-sarcoma of the head of the tibia and fibula.

2407
132
5.

Presented by Dr. Mütter.

6310-42 Osteo-sarcoma of the alveolus of the inferior maxilla (epulis).

2433
133
4.

Presented by Dr. Mütter.

6310-43 Osteo-sarcoma (epulis) of the jaw.

2435
133
5.

Presented by Dr. Mütter.

6310-432 Osteo-sarcoma (epulis) of the superior maxilla.

2434
133
5.

The tumor is large and embraces a portion of the hard palate and connected with it are both incisor and molar teeth.

Presented by Dr. Mütter.

✓ 6310.44. Osteo sarcoma of the r. Knee-joint.
2505
135
6

Duration about 6 or 8 weeks. Case of James Sherrard aet. 18, finisher, worked upon his knees at Shipyard. Amputation by Dr H.R. Wharton at Presbyterian Hospital June 20, 1899. Metastasis to the left lung and death September 18, 1899. Presented by Dr. Guy Hinsdale

✓ 6310 445. Section of Osteo-Sarcoma.
2436.
133.
5.

6310-45 Section of an osteo-sarcoma.

2437.
133
5.

Presented by Dr. Mütter.

6310-47 Osteo-sarcoma of the lower third of the femur; partial disorganization of the bone.

2438
133
5

Presented by Dr. Mütter.

6310-48 Osteo-sarcoma of the tibia. Enormous.

Presented. Sec 91-4.

6310.49 Sarcoma of the right ovary.
2439.
133
5
Case of Emma Tice. MAR 15 1893 Presented by Dr, Baldy.

6310-50 Sarcoma of the left ovary with portions of the omentum
2453.
134.
2. containing nodular sarcomatous masses; with the uterus and right broad ligament and right ovary. From a girl aged 13 years. Besides the above conditions, the peritoneum was studded with nodules of sarcoma.

Presented by Dr. J. Ewing Mears.

6315.5 Section of Melano-Sarcoma from Choroid.
2455.
134.
42.
Pres. by Dr. C. A. Oliver.

6315 Melanotic sarcoma of the eye-ball.
2454.
134
2. The globular form of the ball and the optic nerve are well seen. The growth is situated anteriorly, is dark and of decidedly fungoid character.

Presented by Dr. Mütter.

6325.[1] Leprosy-
2457 ~~2456~~ 134 3. Part of the right foot of a Hindoo leper (John Colston) aged 50. Anaesthetic leper 16 years.
From the Trinidad Asylum. Presented by Dr J.C. Wilson.

6325.[2] Hand from William Green a tuberculated
~~2457~~ 2456 134. 3. leper negro for 11 years. Age 17 years.
From the Trinidad Asylum. Presented by Dr J.C. Wilson.

See Trans. College of Physicians, 1894.

missing
6340.10. Tubercular bodies taken from cyst in groin
Presented by Dr. De Forrest Willard - 4.17.01
See Trans. Amer. Surg Ass. Volume. 18 P. 345 - 1900

6350 Tumor (fibrous?).
2458.
134.
3.

6350-10 Large lobulated fibrous tumor.
2409
132
6

Presented by Dr. Mütter.

6350-15 "Fibro-plastic tumor of the hip."
2561.
137.
4.

Diameter, 18 cm.

Presented by Dr. Mütter.

6350-25 Lobulated fibroma.
2459.
134.
3.

Presented by Dr. Mütter.

6350-30 Fibrous tumor. 2460. 134 3.

6350-35 " " of the neck.
2469.
135
1.

Purchased.

6350-40 Fibrous tumor; lobulated.
2470.
135.
1.

Presented by Dr. Mütter.

6350-42 Fibrous tumor from the shoulder.
2471
135
1.

Presented by Dr. Mütter.

6350-45 Fibrous tumor with a cavity.
2472
135
1

Presented by Dr. Mütter.

2473 135
6350.48 Fibroma of the uterus. 3 months growth. Presented by Dr. J.C. DaCosta.
6350.49 Missing " " " Presented by Dr. J.M. Baldy. 1893 2508 136 1.
6350-50 Fibroma of the uterus.
2509.
136.
1.

Presented by Dr. W.L. Atlee.

6350.51 Uterus and fibroids

2519
136
1

Presented by Dr J Stansbury Sutton 1893.

2481 6350.511 Uterine Fibroid — " " B.C. Hirst
136
3 6350.512 " " " " J.C. DaCosta

2461.
134.
4.

6350.52 missing Uterus and fibroids, with ovaries and tubes.

Removed and presented by Dr Joseph Price.

6350.53

2511
136
1 Fibroma of the left Broad Ligament. No attachments to either tube, ovary, round ligament or uterus. Blood supply of pedicle from near insertion of Uterine artery. Size 8" x 7.5" x 4".

1898. Presented by Dr Jno C. DaCosta.

6350.54.

2542
137.
1 Fibroma of Anterior wall of Vagina. The tumor reached from the cervix to beyond the opening of the urethra. Measured 4.5" x 3.5" x 2.5".

Presented by Dr Jno. C. DaCosta.

1898.

6350 62 A Fatty Tumor from the Arm
2479.
135
2.



V6

V6

V6



6350-55 X Fibroma from the jaw.
2543.
137.
1.

Presented by Dr. Mütter.

6350-60 X Fibroma.
2544.
137.
1. The surface of this tumor is apparently skin. There is so much pigment as to suggest that it is from a negro.

Presented by Dr. Mütter.

6350-65 X Fibroma.
2545
137.
1.

Presented by Dr. Mütter.

6350-70 X Fibroma.
2546.
137.
1.

Presented by Dr. Mütter.

6350-75 X Fibrous tumor from the scalp.
2547.
137.
1.

Presented by Dr. Mütter.

6350.76 X Fibroma of the Ear
2476
135
2

" " Dr. J.B. Roberts.

6350-80 Fibroma. Missing
2477.
135
2.

Presented by Dr. Mütter.

6350-81 X Fibroma of the foot.
2478
135
2. A series of ten (10) small tumors removed for the relief of pain, by Dr. Hunt.

Presented by Dr. Wm. Hunt.

6350-85 Fibroma.

2548.
137.
1.

Presented by Dr. Mütter.

6350-90 Fibroma of the ear. Missing

2549.
137.
1.

Presented by Dr. W.L. Atlee.

Missing

6355 Erectile fibroma;"mollusciform."

2550
137.
1.

The tumor is small,less than an inch in diameter. It has a wrinkled exterior of skin and was pedunculated.

Presented by Dr. Mütter.

~~6360.~~

~~6360.1~~ Photograph #Pkg. 15825 #53 Among Illustrations

Photograph Keloid tumors of back.

These keloids followed removal of tumors 2 years before — The woman says the tumors removed were "blood tumors" —

Presented by Dr John B. Roberts
5.24.01

6370 01 A
2838
134
2.
Sepoma of Back. Removed May
Pres by W. S. Rodman. 11.4.01





## Fatty TUMORS.

6370 Fatty tumors; Lipomata.

6370-05 Large lipoma of the arm. *Spoiled.*

The tumor is 12 cm. in diameter; it is encapsulated.

Presented by Dr. Mütter.

6370-10 *Missing* Lipoma of the shoulder. Diameter 10 cm.

2512
136
2.

6370. 11 A
2474.
135
2.
*Lipoma of the back.*

Presented by Dr. Mütter.

Presented by Dr John B. Roberts.

6370-15 *Missing* Large lobulated lipoma.

Presented by Dr. Mütter.

6370 16
2475.
*Missing*
*Tumor.* Pres by Dr. John B. Roberts.

6370-20 *Missing* Lipoma from the thigh; lobulated.

2513.
136
2.

Presented by Dr. Mütter.

6370-25 *Missing* Lipoma of the neck.

2514
136
2.

Presented by Dr. Mütter.

6370-30 A Loblulated lipoma.

2515
136
2.

Presented by Dr. Mütter.

missing

6370-35 Lipoma from the arm.

The tumor is spheroidal and is not lobulated.

Presented by Dr. Mütter.

6370-40 Loblulated lipoma; small.

2516
136
2.

6370.42 missing

2518
136
2.

Lipoma from within the bursa of the knee. Presented by Dr. John B. Roberts.

Presented by Dr. Mütter.

6370-45 Lipoma of the right shoulder.

2517
136
2.

From a lady aet. 63. Duration 8 years

Presented by Dr. Harris A. Stocum.

6370-50 Small lipoma from the neck.

2519
136
2.

Presented by Dr. Mütter.

6370.55 missing

Congenital tumor of a child 6 weeks of age removed from the coccygeal region - Dubois Pa. April 4th 1901.
(Fibro. lipoma)
Presented by Dr John B. Roberts

## MYXOMATA.

6380. Myxoma- foetal.

2520
136
3.

The growth occupies the anterior portion of the neck, hanging from the inferior maxilla; extending from the jaw to the xiphoid cartilage.

The two halves of the body are imperfectly developed. There was marked oedema of the head and face. The heart was large; the kidneys, thymus gland, and abdominal organs normal.

There was great hydramnios. The foetus was expelled at the twenty-sixth week.

Presented by Dr. Daniel Longaker

6380-10 Myxoma of the nose.

2551.
137.
2.

Presented by Dr. Mütter.

## ENCHONDROMATA.

6390. Enchondroma of the hand and thumb.

2482
135
3.

The tumor is enormous, consisting of large rounded masses of firm consistence springing from the bones of the hand and thumb. The terminal phalanx of the thumb is not involved.

Presented by Dr. Mütter.

6390-05 Enchondroma of the thumb.

2551
137
2

The tumor is of firm consistence. It was completely covered by skin and sprung from the first phalanx of the thumb.

Presented by Dr. Mütter.

6390-10 Enchondroma of the arm. Diameter 12 cm.
2553.
137.
2

Presented by Dr. Mütter.

6390-15 Enchondroma of the hand.
2554.
137.
2.

Presented by Dr. Mütter.

6390.20 Fibrochondromatous adenoma from the Cervical Region.
2555
137.
2.
Presented by D a.v. Meigs.

## OSTEOMATA.

6400. Bony tumor of the scalp.
2556.
137
2.
This growth is flat and was in intimate contact with the skull.

Presented by Dr. Mütter.

6400-05 Exostosis from the back of the hand.
2557.
137.
2.

Presented by Dr. Mütter.

6400.06 Osteoma of the R. Femur " " " Mears.
2483.
135
3.

6434 ~~Cancer of the Uterus and Ovaries~~ missing
2484.
135
3.
~~Pres. by Dr. J. M. Brysdale~~



6470.74. Stomach: cancer of the pylorous
1847 The stomach is of large size
117 Destroyed
see - Vol. I. p. 1735



6450. Venereal warts. (Papilloma). Pres. Dr. Mütter
6450.01 Papilloma of Broad Ligament. Presented by Dr Drysdale
2493
135
4.

Presented by Dr. Mütter.

6450.10 Papilloma of the Tonsil " " " J.B. Roberts
2485
135
3
From a girl aged 18. Duration 2 years

6470. "Scirrhus" of the neck.
2487
135
3.

Presented by Dr. Mütter.

6470-05 "Scirrhus" of the neck.
2488
135
3.

Presented by Dr. Mütter.

6470.09 Scirrhus of the breast. Presented by Dr. Roberts.
6470-10 Scirrhus of the breast.
2480
135
2.

Presented by Dr J Ewing Mears.

Presented by Dr. J. Ewing Mears. 2521 136 3

6470.11 Scirrhus of the breasts " " Dr John B. Roberts.
6470.12 missing " " " " " "

6470-13 Scirrhus cancer of the humerus.
2541
136.
6.

The specimen consists of the humerus and scapula and clavicle. The growth is situated in the upper third of the humerus; it adapted itself to the space between the acromion and the coracoid process of the glenoid fossa of the scapula and then expanded into an ovoidal tumor, which covered the upper third of the humerus. The subject from whom the speciman was procured showed marked deformity of the thorax. The tumor was firm; on section the roughened end of the humerus was seen perforating the lower portion of the mass. Of the head of the humerus, nothing was left but shell.

Microscopic examination showed well marked characteristics of scirrhus - a dense net work of fibrous tissue into the interspace of which are crowded small, irregularly-shaped nucleated cells. In the interior of the growth, in the space

formerly occupied by the marrow of the bone, is a soft granular mass, exhibiting beneath the microscope, large epithelioid cells, among which are interspersed numerous giant cells.

6475. Encephaloid cancer of the subserous tissues of the peritoneum and pleura.

2522
136
3.

The cancerous mass filled the pelvis, enclosing the right ovary; it did not involve the remaining genito-urinary organs, but compressed the walls of the great intestine. On the left, a sac four inches wide and full of serum was seen between the uterus and sacrum. Two similar cavities were found, one high up and one on the right side of the mass. Numerous round cancers were found around the pelvic brim, lying on the folds of the mesentery, the meso-colon and omentum. A large tumor was situated at the angle of the diaphragm and right lobe of the liver; other cancers lay around the gall-bladder, but did not enter the substance of the liver.

Secondary cancers were found in the right kidney and lung. There was bronzed skin, but the renal capsules were healthy.

Microscopic examination by Dr. William Pepper confirmed the cancerous nature of all the nodules found and the innocence of the supra renal bodies.

From a woman, aged 62 years, who died after an illness of 18 months. Emaciation, constipation, nausea, ascites, sacral and lumbar pain, and hyperaesthesia of the left leg were prominent symptoms. During the last four months, the skin assumed a bronze hue.

3:35

See Trans. Path. Society, Philadelphia, March 1867.

Presented by Dr. S. Weir Mitchell.

8476.
2494
135
4.

Medullary cancer of the thigh.

The tumor is from the anterior surface of the thigh. It measures in the circumference of its long diameter,42 cm.,and in its circumference transversely 32 cm. It is lobulated and eucapsulated. In the base of the tumor,running in the direction of its long diameter,is a layer of muscular tissue,the fibres of which are granular,broken and fatty;there is an excess of fibrous tissue and considerable interstitial fatty degeneration. The capsule,which seems to rise from the layers of fascia and sheaths of the muscles,is very firm and, in places, 13 mm. thick.

The lobes of the tumor vary in size from a cherry to one which composes almost half the entire mass. The hardest cut almost like cartilage,presenting a smooth,firm and slightly granular section,whereas the softest are very doughy and their structure loose and broken.

Under the microscope,the softer portions contained little else than the granular debris of cells mixed with a grat proportion of oil globules and granular fat;other portions rather more consistent contained some fibrous structure, altered cells and nuclei,much fat and granular debris;the hardest lobules showed a moderate amount of fibrous tissue rarely forming distinct areolae,with cells and free nuclei clustered together in a delicate blastema;the cells varied much in size;none of them were notably large;some contained one,others,three,four,or more nuclei.

From Mrs. Mc.D.,aged 47. The growth was of one year's duration. A soreness was first felt at the junction of the upper with middle third of the rectus femoris muscle of both thighs. This soreness subsided on the right side,but continuing on the left,formed a tumor the size of a fist by the expiration of three months. Oedema and dysphagia terminated



X Epithelioma of the jaw.

6480.25 ~~Osteo-saroma of the region of the knee.~~

X

6480.30 ~~Epithelioma of the jaw.~~ Osteosarcoma of the region of the knee



life.

Trans.Path. Society, 2:195 Philadelphia, Nov.14th.1865.

Dr.S.Weir Mitchell,

olmesburg,Pa.

V. 2 p. 429 a

NOTE ON 6480.20

Epithelioma of Foot - Resembles Papilloma.

p. 429 a

V

6480.

2523
136
3.

6480.0

2539.
136
6

6480-05

6480.06

2506.
135
6.

6480.08

252
13

6480-10

2531.
136
5.

6480.15

6480-20

2532
136
5

6490

6500

2533.
136
5

6510.

2534
136
5

Dr. Mütter.

Dr J.H. Packard.

ronic ulcer -
hilat June 20. 1899

Dr. Mütter.

" Drystals

fingers about

e index and middle

rformed,

Dr. Mütter.

eight months

Epithelioma -
nsented by Dr O.H. Allis.

ot are the seat

gatation, resem-

torn, and are

John B. Roberts 1.11.95

Small melanotic tumor.

Presented by Dr. Mütter.



X Epithelioma of the jaw.
6480.25 ~~Osteo-saroma of the region of the knee.~~
6480.30 ~~Epithelioma of the jaw. Osteosarcoma of the region of the knee~~



life.

Trans.Path. Society, Philadelphia, Nov.14th.1865. 2:195

Presented by Dr.S.Weir Mitchell,

for Dr.Peale of Holmesburg,Pa.

V
6480. Epithelioma of the lip.
2523
136
3.

X
Presented by Dr. Mütter.

6480.01 Epithelioma of the hand " " Dr J.H. Packard.
2539.
136
6

2524.
6480-05 136. Epithelioma of the lip.
3.

6480.06 " " " " post formed on a chronic ulcer -
2506. amputated by Dr Wharton. Presbyterian Hospital June 20. 1899
135 Presented by Dr. Wharton.
6.

V Presented by Dr. Mütter.
6480.08 Cancer of the bowel - " " " Dr Stacy
2525
136

X
6480-10 Epithelioma of the fingers.
2531.
136
5.

The disease has attacked the dorsum of the fingers about the metacarpo-phalangeal articulation of the index and middle fingers.

From a case in which amputation was performed,

Missing
6480.15 Tumor from the left inguinal region removed eight months after a primary amputation of the penis for Epithelioma. Presented by Dr. Mütter.

6480-20 Epithelioma of the foot. Presented by Dr O.H. Allis.

The heel and inner malleolus of the left foot are the seat of an epithelioma which, in its exuberant vegetation, resembles papilloma. The tufts are large, easily torn, and are prominent.

2532
136
5

6490 Tumor from beneath the quadriceps Extensor Mary Parks aet. 17. Presented by Dr John B. Roberts 1.1.1895

6500. Cervical Tumor. Presented by Dr Roberts.
2533.
136
5.

X
6510. Small melanotic tumor.
2534
136
5

Presented by Dr. Mütter.

6511. "Cancroid" Tumor. Presented by Dr. Mütter
2535
136
6

6511.10 "Cancroid Tumor (missing) Presented by Dr. Mütter.
2536
136
5

6512. Encysted Tumor; from the Shoulder.
2537
136
5. Presented by Dr. Mütter.

6513. Fungous Tumor; removed by ligature.
2538
136
5. Presented by Dr. Mütter.

6531.5
2839.
134
2. triangle. Cystic Tumor removed from Submaxillary triangle. Clinic Kentucky School of Medicine. Pres. by Dr. W. L. Rodman.
Remounted Jan. 24.02.





ANGEIOMATA.

6520. An erectile tumor of the jaw.
2490.
135
4.

The tumor is quite small and to it are attached two teeth, canine and an incisor.

Presented by Dr. Mütter.

2491. 6530. Sac of a cystic tumor.
135
6530.01 " " " " " of the back Dr. Roberts.
2462.
134
5.

Presented.

6530-10 Sac of a cystoma.
2492
135
4

The sac is thin and consists of an inner thin and delicate layer of white fibrous tissue and an outer layer darker and stronger. There is nothing in the specimen to indicate its locality. Diameter, 6 cm.

Presented by Dr. Mütter.

6530-20 "Sero-cystic tumor".
2463
134
5.

The tumor is about 7 cm. in diameter and is of globular shape. The walls are apparently thin and distended and on one side covered with skin showing its negro origin.

Presented by Dr. Mütter.

6531.
2495
135
4

Cystic tumor of the neck. Hydrocele.

This specimen, removed from a young child, consists of the larynx, trachea, bronchi and tongue with the large growths constituting the tumor. On the left side, the tumor appears solid; on the right side it is a cyst. The walls are thin and were distended with fluid. In the present specimen they have been artificially distended.

Presented by Dr. Mütter.

6531-10 Congenital cyst tumor (hydrocele) of the neck.

The child died, aged 83 days, of oedema glottidis.

See Med. Examiner, Vol. VI (1850) pp. 257-9.

Presented by Dr. Mütter.

6532. Cystic tumor of the nates from a new-born child. The mother, aged 25, had borne two children previously. The large tumor obstructed delivery and the child was born with the aid of a blunt hook, the thigh being fractured. The tumor is stated to have been on the third day after delivery, of the size of a man's head. Attached to the nates exactly behind the orificium ani and containing a liquid. On the right side at the base of the tumor could be felt by a careful examination and strong pressure through the liquid, another hard tumor in form and size like an egg. Puncture was made on the eigth day; a brownish and then bloody liquid escaped. The child died in a few hours from hemorrhage into the sac.

The viscera were found healthy and did not communicate with the tumor. The sac was shriveled into folds and contained a large clot of blood. It was a perfect cyst; the parietes were dense, covered in some parts, particularly at its

6532.3
2466
134
4





insertion into the nates, with soft conglomeration of blood vessels. The smaller hard tumor, felt inside the sac was formed by cysts having dense but transparent membranes and containing a clear liquid. At no point did the cyst communicate with the spinal column.

Presented by Dr. Keller.

6532-10
2526
136
4.

Cystic tumor of the nates of a new-born child.

The delivery which took place by a vertex presentation was complicated by this large cyst. The sac was punctured before delivery could be accomplished and after the evacuation of about a gallon of a brownish liquid, the child was expelled. The child died about six hours afterward of a capillary hemorrhage into the sac. The latter showed externally the natural appearance of the skin. The walls were about 25 mm. thick. The internal surface was covered on the upper part with a soft tissue which showed under the microscope a rich net work of capillary blood-vessels, very similar to the villi of the intestines. The lower part was covered with a reticulated fibrous tissue. The tumor was inserted between the orifice of the rectum and the point of the coccyx as in the first case, not exactly in the centre, but about two inches to the right side. A careful examination proved that the tumor did not communicate with the vertebral canal.

Trans. Phila. Path. Society, Vol. I. p. 16.

Presented by Dr. Keller.

6533 5x Tumor from the Jaw.
2504
135
5.





6533. Cyst of the thyroid body.
2527
136
34

The walls of the specimen are shriveled, thickened, and corrugated.

From a man. Suffocation being imminent, the cyst was evacuated and two pints of dark fluid were discharged. The cyst refilled in a few weeks and was extirpated by Dr. John H. Packard.

Presented by Dr. J. Solis-Cohen.

6534. Cystic tumor of the scalp.
2500
135
5.

Presented by Dr. Mütter.

6534-05 Cystis tumor of the scalp.
2501
135
5

Presented by Dr. Mütter.

6534-10 Cystic tumor of the scalp.
2502.
135
5.

Presented by Dr. Mütter.

Missing
6534-15 Cystic tumor of the scalp.
2503.
135
5

Presented by Dr. Mütter.

6534-20 Four cystic tumors of the scalp.
2567
137
5

Presented by Dr. Mütter.

6534-25 = 2568
137
5
6534-26 = 2569 = 137
6534-27 = 2570 = 5 Tumors of the scalp.

## CYSTOMATA.

6535-05 Cyst of the ovary.

2528
136
4.

A large unilocular ovarian cyst.

Presented by Dr.Washington L. Atlee.

missing

6535-10 Multilocular ovarian cyst.

2529.
136
4.

Operation Spetember 21st.1853. Mrs.E.S.,aged 26. Very much prostrated and suffering great agony Diseases of six months duration and progressing rapidly. Incision from umbilicus to pubis. Tumor cystic form,strongly and extensively adherent; several cysts gangrenous,rotten,and filled with pus. Weight 40-lbs. Anaesthesia. Death in 22 days from a gangrenous perforation of the jejunum one inch in diameter.

Am.Jour.Med.Science April 1855,p.391.Case XXIII

Presented by Dr.Washington L. Atlee.

6535-15 Ovarian cyst.

2507
135
6.

Operation April 16th.1851. Mrs. M. W.,aged 29. Incision from near sternum to pubis. Tumor cystiform,firmly and extensively adherent;some peritoneal effusion. Pedicle about six inches broad filled with varicose veins;one very large cyst was filled with partially washed crassamentum and could not be diminished in size by the trocar. Weight of tumor 35 1-2 lbs. Anaesthesia. Death from peritonitis on third day.

Operation done in N.W.Connecticut and in the midst of that terrific storm that blew down the Boston light house. The room occupied by the patient was the best in the house and yet the wind and rain had free access to it.

Am.Jour.Med.Science April 1855,p.390.Case XV.

Presented by Dr. Washington L.Atlee.

[Reprinted from THE MEDICAL NEWS, May 26, 1894.]

6535.16 { 2572 1347

# EXTRA-UTERINE PREGNANCY SIMULATED BY A SMALL TUMOR OF THE OVARY; OPERATION; RECOVERY.

Presented By WILLIAM H. MORRISON, M.D.,
OF PHILADELPHIA.

THE possibility of diagnosticating extra-uterine pregnancy before rupture of the sac has in the past received considerable discussion, but at present the generally accepted opinion is that such a diagnosis cannot be made with any great degree of certainty. A case on which I recently operated illustrates with such force the uncertainties attending the diagnosis of ectopic gestation that it seems worthy of record.

The patient, Mrs. X., thirty years of age, the mother of four children, has been under my personal observation for a number of years. In November, 1893, that is five months ago, she had a miscarriage at two or three months, from which she recovered without incident, with the exception that a slight tendency to bleed continued. For this I curetted the uterus some two weeks later. In the repeated examinations made at this time, nothing abnormal was detected in the pelvis. Following the miscarriage, menstruation recurred every twenty-four days, until February, when the period which should have commenced February 27th did not appear until March 11th, twelve days overdue. It, however, presented nothing unusual as far as the patient observed. Two weeks later, March 27th, she was taken with sharp recurring pains in the lower part of the abdomen, some-

what more severe on the right side. After a few hours these passed away, to reappear on the following day. With the pains there was a slight discharge of blood from the vagina. It was at this time (March 28th) that I was called. The pain, while acute, did not seem to be of great severity. There was no shock, no alteration in temperature, no disturbance of pulse. There was tenderness over the whole of the lower part of the abdomen not especially localized. There was no gastric or intestinal disorder to explain the abdominal tenderness.

Vaginal examination showed the uterus to be slightly enlarged. On the right side of the pelvis nothing abnormal could be discovered, but to the left of the uterus and low down was a globular mass, apparently one and a half or two inches in diameter, which seemed to be a cyst. It was quite tender on pressure, but could be displaced upward to a certain extent. This mass while in contact with the uterus was distinct from it. A sound introduced into the uterus gave a measurement of three inches, and as it was removed brought away two or three shreds of thin membranous tissue.

A diagnosis of cystic tumor in the pelvis, probably an extra-uterine pregnancy, was made, the condition of affairs explained to the patient and her husband, and operation advised. This was acquiesced in, and on March 31st I opened the abdomen and removed a tumor which was found to be the left ovary in a state of cystic degeneration. The tube was normal. The right ovary was brought to the abdominal incision, but as it was small and presented no evidence of disease, it was allowed to remain. The after-course of the case was uneventful and the recovery complete. The enlarged ovary was ovoid in shape, and about two inches in its longest diameter. It contained three cysts. At its outer extremity was a small cavity containing about twenty minims of dark fluid blood, evidently due to a recent hemorrhage. This probably was the explanation of the sharp abdominal pains. A second small cyst at the opposite extremity was filled with clear, watery fluid, while the bulk of the tumor was made up of a cyst containing amber-colored gelatinous material.

6538.10
2464.
134
5.
Pres. by Mr. Wm. Ashhurst.

6538.04
2559.
137.
4.
Pres. by Mr. W. W. Ashhurst.

6538.05
Death from Dermoid Cyst.
2571.
137.
5.
Pres. by Dr. Mears.

6550 02.



missing

453

6535-20 Cyst of the ovary.

Operation September 14th, 1853. Mrs. S.R., aged 56. Enormously enlarged and a great sufferer. Incision from umbilicus to pubis. Tumor cystiform, extensively adherent; considerable peritoneal effusion; pedicle broad and vascular. Weight 50 lbs. Anaesthesia; recovery.

Amer. Jour. Med. Science, April 1855, p. 391. Case XXII.

Presented by Dr. Washington L. Atlee.

6538 2530 136 4. Dermoid cyst of the ovary.

The cyst is of a globular shape, about 8 cm. in diameter and, as mounted, shows a thick capsule of fibrous tissue enclosing a cavity partly filled with a firm body resembling the scalp, from which grow hairs and teeth. The hair is long and fine. The remaining portion of the cavity contained sebaceous matter, which was dissolved by ether previous to mounting.

Removed from a woman aged 23, by Dr. T. Addis Emmet.

Presented by Dr. Wm. Hunt.

missing
6538.50 Dermoid Cyst. 2577. 137. 5.

6538.60 Dermoid Tumor from the floor of the mouth of a man aged 23 years 2497 135 5
Presented by Dr. H. R. Wharton.

6539 Hair from a dermoid cyst. 2498 135 5.
Pres. by Dr. W. F. Atlee

6539.10 Dermoid Cyst; With hair. Presented by Dr. J. Price.

6539.20 Dermoid cyst of the left ovary from a child aged 4 years containing hair and bones 2499 135 5. Presented by Dr. W. C. Goodell.

6550 2573. 137. 5. Hypertrophy of the thyroid body.

The tumor consists of an irregular, nodulated mass having a long diameter of about 6 cm.

Presented by Dr. Isaac Parrish.

6550-05 Thyroid body; hypertrophy; calcareous degeneration; (goitre).

2574. 137. 5.

The greater hypertrophy is on the right side. The growth

p. 457 a

produces a large prominence of the trachea.

Presented by Dr. Mütter.

X

6550-07 Hypertrophy of the thyroid body.

2576.
137.
5.

Preo. by Dr. Mütter

X

6550-10 Thyroid body;hypertrophy;(goitre).

2575
137.
5.

The lateral halvesof the thyroid body are equally hypertrophied;their vertical extent is about 8 cm.

A section shows to the naked eye a fine reticulum of fibrous tissue filled with innumerable blood vessels.

Presented by Dr. Mütter.

Presented by Dr. Mütter.

IX

6550-15 Thyroid body;heart and large vessels;larynx and appendages;hypertrophied thyroid;(goitre).

2560
137.
4.

The thyroid body is enormously hypertrophied and has a supply of blood through large vessels.

Presented by Dr. Mütter.

# TERATOLOGY.

## Monsters.

7000.

7000. Siamese Twins.

7001.a Sketches relating to the autopsy of the Siamese twins. Sec. 77- Closet a.

7001.b- Photographs of Siamese Twins at autopsy. Sec. 77- Closet a.

7001.c. Scrapbook of Siamese Twins. Section 77- Closet a.

For other sketches see large portfolio #15811- Sec. 77 Drawer B-7

IX

7003. Bicephalic Monster
Ischiopagus tripus.

These twins were born in Warren County, Ohio, Oct. 12th, 1870, the delivery being natural and easy, and accomplished half an hour before the arrival of the attending physician. By reference to the ~~accompaning photograph~~ plaster cast it will be seen that these babes have a common trunk, terminating at either extremity in a well shaped neck and head. Each end of the trunk is formed of a perfect thorax with its contained viscera, then comes the swell of the belly, and the children insensibly grade into one another. As they lie extended upon their backs they look as if two children had been cut transversely across at their umbilici, and then accurately welded together.

Exactly in the centre of their common abdomen is a scar, making the attachment of the umbilical cord, of which there was but one, along with one placenta, and these of usual size.

Springing at right angles from the right side of the abdomen is a well formed pelvis supporting a perfect pair of legs and feet, with the exception that one of the latter is in a condition of equino-varus. To these extremities are attached the genital apparatus and anus of an ordinary female child. Upon the opposite side of the abdomen there appears to be a rudimentary pelvis in the shape of an ilium, feeling under the skin something like a scapula. Branching from this also at right angles to the body, is a compound rudimentary leg, its anterior aspect looking backwards, terminating in a foot containing two ossa calces and eight toes -the great toes being outermost, and the lesser ones side by side.

When the child lies upon its belly, with its arms folded into the side and its legs extended, it is cross-like in shape, - one arm of the cross being represented by the rudi-

spines, on first inspection, seem to be continuous, but closer examination shows that they come together like two J's with their crooks laid end to end, thus , the crooks turning towards the right and being attached to the complete pelvis.

One of these children is ruddy, muscular and full of vigorous vitality; but the other is thin, its chest is deficient in development, and its face looks prematurely old. The mother at first nursed them both, but now gives all her milk to the smaller one, feeding the larger child from the bottle.

The father of these children is a tall, gaunt Pennsylvanian, forty three years of age, a farmer; the mother is an Ohioan, thirty three years of age, of massive frame and heavy face. She has had three other children, all healthy, the eldest being thirteen years of age. She knows of no cause to which to ascribe the productionof such strange progeny.

The pulse of these children is not uniform, beating at one examination six times faster to the minute in the arm of one child than in the arm of its companion. The sensation is also different. One does not feel when the other is pinched; one feeds while the other sleeps; and their separate attentions are simultaneously attracted by different objects. It is the opinion of their physician, Dr H. Besse, of Ohio, that they have separate bladders, owing to one bearing down and making water and a few minutes after the other, with like exertion, repeating the operation. The history of these cases, however, is that they have but one bladder and one rectum.

These children were placed at the disposal of Dr. S. W. Gross, to whose courtesy I am indebted for the opportunity of making this report. They were also the subjects of a clinical lecture at the Jefferson Medical College, by Dr H. F. Getchell, who ranked them in the order Catadidyma, genus Ischiopagus, and species Ischiopagus Tripus.

To show how typical this child is of its class, the lecturer exhibited cuts of three similar cases, one born in Oxford, England, in 1552, one in Ceylon, many years after, and one in Cadiz, Spain, in 1818. The former two died at birth, the latter survived five days. This then is a much greater curiosoty as a representative of a recognized class, all recorded cases of which have died at or soon after birth, than if it were a mere chance formation.

The history of all double monsters is that the death of one is immediately followed by the death of the other, and the present case seems to afford no chance for deviation from this rule. At present their digestio- and assimilation are good. They are visited daily by hundreds of people, and maintain rare infantile good humor in spite of the somewhat awkward handling and examining they are ofttimes subjected to.

The twins lived over thirteen months; the emaciated one died first and a few moments later the other followed. No autopsy allowed.

Dr. R. M. Townsand. Photographic Review, Vol.I. p,58 1870-1,

missing

7005.
1671
101
/

Double monster, showing two heads and trunks; abdominal union; three legs and a fourth rudimentary. An early foetus.

Presented by Dr.Goodell and Dr.J.T.Fuller ofN.C

(Cephalothoracopagus Monosymmetros) 561

7010.

434
Sec 15
Shelf 1

Skeleton of a double monster.

The skeleton measures 33 cm. in length. The head has an occipito-mental diameter of 10 cm. and a biparietal diameter of 8.8cm. The anterior and superior surface of the head is single; the duplication commences at the base of the cranium. The bones of the face are those of a single head with the exception of an effort at a double formation of the inferior maxillary bone and of the palate processes of the superior maxillary. The frontal and parietal bones are those of a single head; there are two occipital bones. To the condyloid processes of each are articulated the atlas of each vertebral column. There are two temporal, and two imperfect sphenoid bones.

Below the head the skeleton is completely double. The thorax was a single cavity, having two sterna to which the ribs and clavicles are articulated in a very peculiar manner. The right ribs and clavicle of the right skeleton and the left ribs and clavicle of the left skeleton articulat with the anterior sternum. The left ribs and clavicle of the right skeleton and the right ribs and clavicle of the left skeleton articulate with the posterior sternum. The other bones of each skeleton were developed and articulated as usual/

This monster was delivered in 1851 by Dr. Warrington of Philadelphia it being the third pregnancy of woman aged 28 years. No unusual prenatal mental impression is recored. The four feet presented first; the head being born last and the whole labor was unattanded by any disaster to the mother.

The recent external appearance was that of two children having a thorax in common but with a single head. There was a fissure of the lower lip of the face in the median line. On the back of the head there was a symmetrical double ear, the meatus of which was imperforate. The four upper and the four lower extremities were perfect, equally developed and natural in their positions.

The umbilical cord was very thick and consisted of two umbilical veins and four umbilical arteries, one of which was very large, and the other very small; each part entering its own placenta.

The mouth was a single cavity, containing two tongues separated posteriorly by an irregular mass covered with skin, which was probably a rudimentary cheek or lip. The fauces and upper part of each pharynx were distinct; each contained a and two tonsils.

The pharynges communicated and, from the funnel-shaped cavity formed by their junction, there proceeded a single oesophagus. The oesophagus terminated in a stomach containing a single cavity though its shape was such as to give the idea that two stomachs had been fused by their lesser curvatures.

From the pylorus, there extended a single intestinal canal, which, at a distance of two feet from the stomach divided into two distinct tubes, each about 40 cm. in length. These had the characters of the small intestine and terminated regularly in the ileo-colic valve. The large intestine

was completely double, there being one for each child each was perfect from the caecum to the anus, not excepting the appendix vermiformis and contained the usual amount of meconium.

The liver was single, large and symmetrical; it contained two lobes about the same size and a single gall-bladder. A spleen and two well-formed kidney were found in each trunk. The genitals, which were female, were perfectly developed, both externally and internally in each pelvis.

Organs of respiration normal for each child, that except at the apices of the lungs of the right child a large vessel entered.

There were two hearts; one was rudimentary and situated between the lungs of the left child; it was conical in its shape; consisted of but one single cavity and from its base there proceeded a single vessel. The other was developed irregularly; it was situated under the sternum to which are articulated the left ribs of the left child. From the base of this heart there arose an aorta for each child which occupied its usual position on the vertebral column.

The larger arterial branches were regularly given off, with the exceptionof the umbilical arteries of the right child, one of which was very large and appeared to be the continuation of the primitive iliac; the other was exceedingly small.

The ascending vena cava of the left child did not pass through the liver, but, after being joined

by the descending vena cava, the common trunk thus formedpassed behind the heart emptying into the right auricle. The ascending vena cava of the right child did not seem to exist below the liver, but the blood vessels from the lower extremities opened into the portal vein which was large proportionally. The pulmonary artery communicated with each aorta.

For plates etc., See Trans. Coll. Phys. Vol. i. N.S. pp. 90 and 171.

Presented by Dr. Warrington.

7011 1672. 101 1 — Cast of a double-headed monster.

"no gross deformity of the face" - Dr. McFarland.

7015. — Monster; deformity of the face.

7016 1673 101 1 — Spina Bifida: from a I Para - at term. Presented by Dr. J. R. Bryan.

(Craniorachischisis)

7020. — Anencephalic skeleton; spina bifida.

435 Sec 15 Shelf 1

The foetus was probably nearly of full term. There is no cranial cavity. The posterior arches of the cervical and first five dorsal vertebrae are wanting.

7021. — Anencephalic skeleton; complete spina bifida.

436 Sec 15 Shelf 1

The foetus was perhaps of eight months gestation. There is no cranial cavity and there are no posterior arches throughout the entire spinal column.

Presented to the Museum by

T. V. Rohon, Vienna.

7042.15. Anencephalic female foetus. Spina bifida
1678
102
1





1145.72
~~7040.~~ Hydrocephalic skeleton;foetal.
437
Vol. I. Pg. 479
sec ~~15~~
shelf ~~34~~ sec 8

Presented by T.V.Rohon,Vienna.

1090.451
~~7040-10.~~ Hydrocephalus. Vol. I. Page 380
~~[illegible]~~ sec 30 sh 6
Red

Presented by Dr.H.A. Kelly.

7041. Anencephalic female foetus;spina bifida.
1674
101
1

7041-5. Anencephalic female foetus.
1675
101
1

Presented by Dr.Charles W. Dulles.

Presented by Dr. J.M. Corse.

7042. Anencephalic ~~female~~ male foetus. August 5, 1884 (from accession book
1676
101
1

Presented by Dr.J.M. Keating.

7042-10. Anencephalic female foetus;spina bifida.
1677
102
1

Presented by Dr.E.K.Wurzel.

7043. Foetus;deformity of forearm.
1679
102
1

The forearm near the wrist is bent upon itself so that the hand points upward. Possibly due to a constriction by the funis. Presented by Dr. Corse.

7044-
1680
102
1

Foetus; club-feet, spina bifida, exstrophy of the abdominal organs, absence of anus and genitals.

The mother, aet. 19 years., a primipara, had felt the movements of the child up to a few hours before it was born. Labor was slow, lasting twenty hours; uterine hemorrhage and severe pain. Delivery occurred without assistance. No assignable cause of the monstrosity.

presented by Dr. F.H. Getchell.

~~Presented by Dr. Corse.~~

same as page 519

7044. Anencephalic foetus.

7045. Anencephalic foetus of seven months; spina bifida.

1681
102
1

The entire spine is exposed and surmounted by a large mass occupying the position of the brain but not covered by skull.

Presented by Dr. Corse.

7046. Anencephalous foetus, of five months pregnancy Oct. 11th. 1889, thrown off March 9th. 1890.

1682
102
1

The heart sounds were always feeble and indistinct, with a rhythm of about 140 to the minute. Father healthy, Mother weighed between two and three pounds at birth herself, but is a fairly developed healthy woman, except that she has an enlarged and hardened left ovary. Miscarried at three months immediately before this conception.

This specimen has been cut so as to expose the appendix and caecum

Presented by Dr. Cheston Morris, M.D.

1902 Mother has since given birth to five healthy children

7047. Foetus monster.

1683
102
1

The abdominal wall, right side, is wanting and through the opening the intestines, omentum, and kidney protrude. Spina bifida and club foot.

F.H.

Presented by Dr. Getchell.

See Trans.College of Physicians of Philadelphia.
Vol.IV, N.S. p.189.

7050. Ethmocephalus, Malformation of the nose. Cast.

The specimen consists of the plaster cast of the head of a male child born at term with a particular malformation of the nose consisting of a tubular proboscis-like organ measuring 25 mm. in length along its upper surface;11 mm. along its lower;20 mm. in width at the base and 12 mm. at the tip. When recent it was flexible;covered throughout with integument,presented a single subrounded nostril,having somewhat turned margins, slightly projected. The interior of this organ appeared to be a cul-de-sac,without communication with the mucous membrane. The forehead was much contracted from side to side,and presented a single frontal protuberance. The palpebral fissures were approximated;each fissure measuring 11 mm. in length and directed slightly downwards and outwards. The space between the eyes was 20 mm. in width and was occupied by the base of the nose.

The child was born alive,cried,breathed imperfectly for nearly an hour and died probably of asphyxia.

For a detailed account of the minute anatomy of the brain with early arrest of development in this case,See Report in Trans. Pathological Society Philadelphia. Vol.V. p.243,by Drs.F.H.Gross,John Guiteras,John M. Keating,and Harrison Allen.

527



5. *Monstrosity. Case of malformation of the nose.*

By Dr. Ferdinand H. Gross.

The monstrosity is the body of a male child born at term with a peculiar malformation of the nose. The organ consisted of a mere cylindrical fleshy tube starting out from between the eyes or the position of the root of the nose, its dimensions being a little over an inch in length and about half an inch in diameter. There was no cartilage of the septum nor columna, and instead of the two anterior nares there was but one small round opening or canal. It was quite soft and flexible, and bore a resemblance to the male organ of an infant.

The case came to my notice under the following circumstances: On the previous day, while visiting a case of frost-bite in the house of a midwife, she informed me that on the same morning a German woman, the wife of a butcher, had been unexpectedly taken with strong labor-pains while standing at her stall in the market, and that there had been only time enough to get the woman into the house of the midwife, which was in the neighborhood, when she gave birth to this child. She reported that it showed signs of life immediately, that it cried, breathed imperfectly for nearly an hour, and then died. The body was quite livid when first shown to me, and the cause of death was no doubt asphyxia.

The mother was twenty-four years of age, and had borne four healthy children.

The specimen was referred to a special committee, consisting of Drs. F. H. Gross, Harrison Allen, John Guitéras, and John M. Keating, for examination and report. *January 15th*, 1875.

*Report of the Committee appointed to examine the specimen of imperfect-cyclops monster presented by Dr. F. H. Gross:*

"Your committee beg leave to report that upon examination they found that the specimen was an example of the deformation known as the *ethmocephale* of Saint-Hilaire, the exact position of the specimen being, it was thought, in close connection with the cyclops group of monsters.

"The body was that of a male child at full term. It presented nothing unusual apart from the head and face, to which your committee's remarks will be confined.

"The forehead was much contracted from side to side, and presented a single frontal protuberance. The palpebral fissures were approximated, each fissure measuring five lines in length, and directed slightly downwards

and outwards. The space between the eyes was nine lines in width, and was occupied by the base of the nose. The latter organ was the most re-

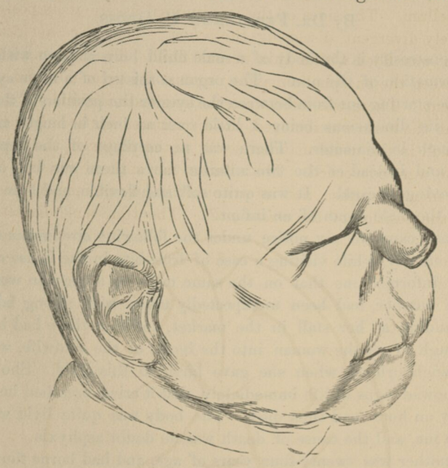

Fig. 11.

View of the Head before Dissection.

markable feature of the specimen. It consisted of a tubular proboscis-like organ, which measured eleven lines in length along its upper surface, five lines in length along its lower, nine lines in width at the base, and five and a half at the tip. It was flexible, covered throughout with integument, presented a single sub-rounded nostril, having somewhat tumid margins, which, towards the middle, both above and below, slightly projected. The interior of this organ appeared to be a *cul-de-sac*, without communication with the mucous membrane.

"The lips were well formed, the oral fissure measuring ten lines in length. The upper margin of the fibres of the orbicularis oris muscle was defined by a well-marked wrinkle. The space between this and the base of the nose was smooth, measured nine lines in height, and was continuous with the cheek surfaces.

"Upon removing the calvaria, it was found that the brain-case was not entirely occupied with the brain, the top of the cerebral hemispheres fail-



ing to reach the sagittal suture by one inch. Its appearance was, moreover, remarkable by the failure of the posterior cerebral lobes to overlie the cerebellum. The sides of the longitudinal fissure at its posterior part were widely divergent, disclosing the *velum*. The space not occupied by the brain was filled with a thin serous fluid. The dura mater sent no folds between the encephalic masses; so that the great falx and tentorium were absent. There was, of course, no longitudinal sinus.

"When the brain was removed, the dura mater was seen lining the base of the skull in the usual manner, so far as the posterior and middle cerebral fossæ were concerned. That lining the anterior cerebral fossa presented a smooth surface, not interrupted by any eminence which would indicate the position of the *crista galli*. The transverse diameter of the

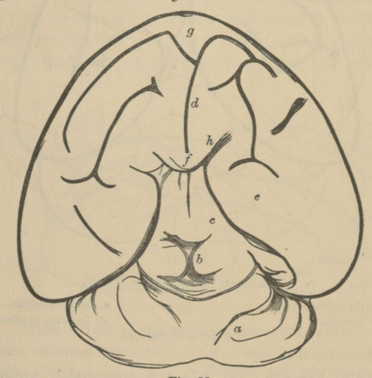


Fig. 12.

The Brain viewed from Above.

*a*. The cerebellum.
*b*. Corpora quadrigemina.
*c*. Probable position of the optic thalamus.
*d*. The median sulcus.
*e*. The occipital lobe.
*f*. The first posterior transverse convolution.
*g*. The first anterior transverse convolution.
*h*. The parieto-occipital fissure.

anterior cerebral fossa was one inch and ten lines. There was no appearance of olfactory grooves or cribriform plate.

"Viewed from above (Fig. 12), the encephalon presented the following appearances: The cerebellum (*a*), corpora quadrigemina (*b*), and optic thalami (*c*) were exposed; the cerebrum terminating four lines in advance of the cerebellum. The cerebrum was imperfectly divided into two hemi-

spheres. The longitudinal fissure was represented by a median sulcus (*d*) measuring nine lines in length, which did not extend downwards to a corpus callosum,—this commissure being entirely absent; nor did this sulcus differ in any respect from those elsewhere seen on the cortex. The occipital lobes (*e*) were not approximated; indeed, it was by their want of approximation that the optic thalami and corpora quadrigemina were seen.

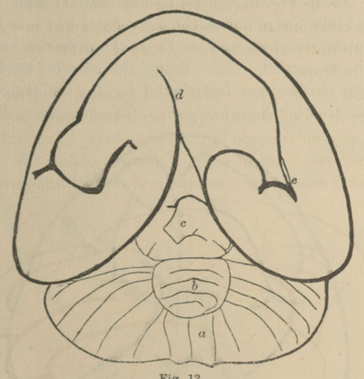


Fig. 13.

THE BRAIN VIEWED FROM BELOW.

*a*. Medulla oblongata.
*b*. Pons Varolii.
*c*. Infundibulum.
*d*. Inferior median sulcus.
*e*. Fissure of Sylvius.

"Viewed from beneath (Fig. 13), the encephalon presented a normal medulla oblongata and pons. There were no mammillary bodies. The under part of the mass, answering to the conjoined thalami, (?) presented a conspicuous infundibulum (*c*). The posterior perforated space was absent; the two anterior were conjoined into a central space placed in advance of the infundibulum. In front of the latter space was a median sulcus, measuring seven lines in length. The olfactory nerves were absent. The position of the optic tract was obscurely defined. No trace of a chiasm was seen.

"The general aspect of the cerebrum led your committee to determine the significance of its malformation to be as follows: that at an early period in the history of the fœtus, at a time when the hemispheres were



about to be discerned, the development of the mass was arrested. A decided attempt at a symmetrical division of its parts was announced, which, however, was not successfully attained in many parts of the cerebrum: thus a right and a left hemisphere were recognized, united by two conspicuous transverse convolutions in front, and by two shorter and less conspicuous convolutions behind. The superior median sulcus was terminated posteriorly by the first posterior transverse convolution. The first anterior transverse convolution presented upon its upper margin a pyramidal offset, which abruptly arose, and was lodged within the superior sulcus, bifurcating it in front.

"In the right cerebral hemisphere the fissure of Sylvius began about a line above the level of the anterior perforated space, and ascended less than half the way up the side of the hemisphere. In front of this fissure were the transverse convolutions, the fissure joining the sulcus between them. Behind it was a large smooth surface which answered pretty nearly

Fig. 14.

PROFILE VIEW OF THE BRAIN SEEN FROM THE RIGHT.

*a*. Anterior superior transverse convolution.
*b*. Superior median sulcus.
*c*. The posterior superior transverse convolution.
*d*. The parieto-occipital sulcus.
*e*. The occipital lobe.

to the posterior half of the hemisphere. The fissure of Rolando began at the anterior border of the superior median sulcus, with which it was continuous, and extended downwards and outwards to the end of the first anterior transverse convolution. The position of the parieto-occipital sulcus was marked by a wide fissure, bounded in front by the posterior superior transverse convolution, and behind by the occipital lobe.

"The left cerebral hemisphere presented a fissure of Sylvius which began at the level of the anterior perforated space, and did not ascend the side of the hemisphere, but was deflected forwards and inwards, to be continuous with the sulcus between the two anterior transverse convolutions.

"The fissure of Rolando passed outwards and backwards, not parallel with the median sulcus, but outwards along the side of the hemisphere to the first anterior transverse convolution. The parieto-occipital sulcus was less deep than that on the right side, but wider. About the posterior third of the hemisphere, below, and at its sides, no convolutions were seen.

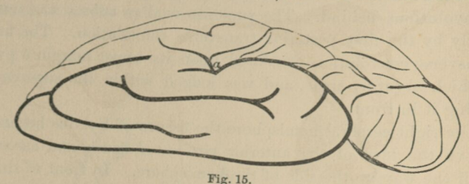

Fig. 15.

PROFILE VIEW OF THE BRAIN SEEN FROM THE LEFT.

*a*. Parieto-occipital sulcus.

"These features represented, it was thought by your committee, the most important points of the superficies. Of minor value would appear to be the presence of a conspicuous sulcus upon the upper surface of either hemisphere, which on the right side joined the fissure of Rolando in front and at its termination, and extended backwards and nearly parallel to the median sulcus, to terminate in the occipital lobe by a Y-shaped flange. A similar sulcus on the left side had no connection with the fissure of Rolando anteriorly, but extended backwards and outwards to terminate in a similar manner with that of the right side.

"Two other sulci were seen, which were not symmetrical: the one on the right was a little depression about the middle of the side of the hemisphere; the one on the left, somewhat larger, seen upon the upper portion of the occipital lobe.

"It will be observed that all the parts are better developed upon the left than upon the right side.

"The interior of the cerebrum was a simple cavity, without any attempt apparent at the formation of *fornix*, *corpus callosum*, or *septum lucidum*. No prolongations were seen in the position of the olfactory nerves. Posteriorly, the cavity was continuous, with a *cul-de-sac* about seven lines in depth, apparently formed by the doubling of the cerebral tissue at that point; and the fold thereby made determined the posterior inferior border of the hemisphere. This *cul-de-sac* your committee took to be in the position of the future middle horn of the lateral ventricle.

"A longitudinal section of the skull was made a little to the right of the



median line; yet so narrow was the pre-sphenoidal portion of the body of the sphenoid bone that the section was directed through the right optic foramen, where an optic nerve was found in position.

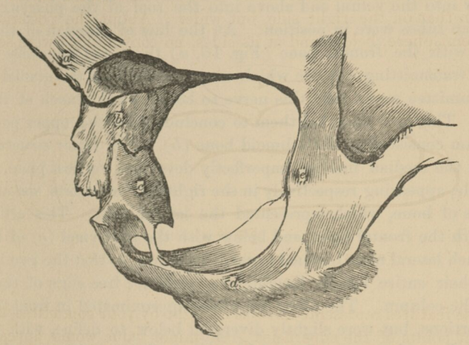

Fig. 16.

PROFILE VIEW OF THE IMPERFECT INTER-ORBITAL SEPTUM SEEN FROM THE LEFT.

*a*. The frontal bone.
*b*. The ethmoid bone.
*c*. The lachrymal bone.
*d*. The superior maxilla.

"An osseous column was now displayed, which extended in the median line from the frontal bone to the intermaxillary bone, and which was thought to answer to the associated ethmoid and lachrymal bones. No trace of the vomer could be found. The above mass measured six lines in height, six from behind forwards, and three in width. It formed an imperfect septum between the orbits, which served to separate these cavities anteriorly only, while posteriorly the eyeballs were surrounded by a common mass of fatty tissue and muscle.

"The section exposed the dental sacs. The left half contained almost the whole of the palate, presenting anteriorly an intermaxillary bone, the outline of which was well marked on the upper or orbital surface. This surface terminated in an anterior nasal spine. This latter process was much more pronounced than is normal, or rather the intermaxilla was deeper than normal, by which the process in question was raised above the level of the orbits. The outer walls of the orbits were normal. The floor was common to both, and was formed by a coalescence of the orbital plates of the superior maxillæ with the intermaxillæ. The infra-orbital canals were in position.

"The hard palate terminated posteriorly in a normal velum. There was no room for the posterior nares: in fact, in their place was found a mere pouch of mucous membrane between the two pterygoid processes, extending below into the velum and above into the roof of the pharynx. The Eustachian tubes were in position. At the line of junction of the nasal columns with the frontal bone (Fig. 16, *a*) there was on either side a foramen transmitting a nerve which was traceable into the cranial cavity. Your committee would take this nerve to be the nasal branch of the ophthalmic. This fact alone led them to conclude that the upper portion of the septum consisted of the ethmoid bone (*b*). The latter structure presented in the median line an imperfectly developed vertical plate, and on either side, appearing respectively in the right and left orbits, was an irregular mass of bone, which represented the lateral mass. This articulated above with the frontal bone, and below with the lachrymal (*c*) of its own side. Each lateral mass inclined towards its fellow, so that the two touched behind their entire length, forming the posterior free edge of the upper half of the column. The plates were also approximated in front, at their upper portions, but were slightly divergent below, to define, with the aid of the lachrymals, an opening which answered in position to the nasal chambers, within which was seen the lumpish perpendicular plate. The lower bone of the septum on either side was undoubtedly the lachrymal. It presented on its outer surface a marked groove which was completed by the ascending portion of the intermaxillæ. On the left side the groove was better marked, the posterior inferior angle of the bone being prolonged into a hook-like process which was attached by ligamentous union to the upper surface of the intermaxillæ. The anterior inferior angle of the bone was attached to the nasal spine of the intermaxillæ. The lachrymal bones converged and touched behind, to form a sharpened edge, which constituted about the lower half of the posterior border of the nasal column. Anteriorly, the bones aid in defining the lower portion of the lateral walls of the nasal chamber. The integument lining the proboscis-like organ was evidently continuous with the true skin-surface, but had united with the parts above described so far as to have entered and been held in close connection with the interior of the rudiment of the nasal chambers.

"The thoracic and abdominal viscera were normal. A section of the lungs floated in water.

"F. H. Gross,
"Jno. Guitéras,
"Jno. M. Keating,
"Harrison Allen."

Made and Presented by Dr. John M. Keating.

7060. Pig.

1685
103
1

A probosis descends for 4 cm. from the fore-head-above and between the eyes.

7070. Chicken;two heads.

1616
48
4

Presented by Dr.C.S. Wurts.

7080. Bird;having a third wing.

1605
48
2

Hermaphrodite. See 9340 ~~(Veneral case)~~.

7083. Cranioschisis with meningocele